

Snakebites in domestic animals

Andreia Garcês^{1,2*}, Catarina Pereira³, Maria Inês Santiago⁴, Justina Prada⁵, Filipe Silva^{1,5}, Isabel Pires⁵

¹Exotic and Wildlife Service University of Trás-os-Montes and Alto Douro, Vila Real, Portugal

²CITAB, University of Trás-os-Montes and Alto Douro, Vila Real, Portugal

³Calweton Veterinary Group, United Kingdom

⁴Santa Marinha Veterinary Clinic, Avanca, Portugal;

⁵CECAV, University of Trás-os-Montes and Alto Douro, Vila Real, Portugal



cras
utad



IECT
2023

The 2nd International Electronic
Conference on Toxins

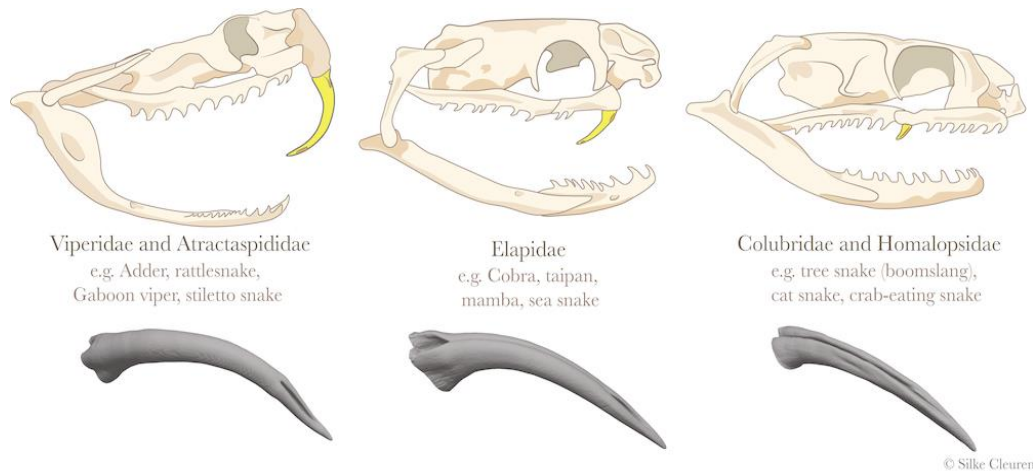
14-28 July 2023 | online

Introduction

In Portugal, there are four venomous species: the horned viper (*Vipera latastei*) (A), seoane (*Vipera seoanei*) (B), rat snake (*Malpolon monspessulanus*) (c) and the hooded snake (*Macroprotodon brevis ibericus*) (D), and in the UK the common European adder (*Vipera berus*) (E).



They possess canaliculated venom devices, that is, hollow fangs located anteriorly in the maxilla, associated with a venom gland, whose content is inoculated at high pressure by compression of the gland by skeletal muscle fibres. Snake venom is a complex mixture of toxins, the composition of which varies depending on the families, genera, and species[6].



Viperidae and Atractaspididae
e.g. Adder, rattlesnake,
Gaboon viper, stiletto snake

Elapidae
e.g. Cobra, taipan,
mamba, sea snake

Colubridae and Homalopsidae
e.g. tree snake (boomslang),
cat snake, crab-eating snake

The annual incidence of poisoning of humans in Europe ranges between 4000 and 20 000 cases, the incidence in animals is believed to be 30 times higher and with a higher mortality rate of 3.5-14% . The data on snakebites in domestic animals are dispersed and still scarce in various regions. The real number of animals affected every year in Europe is unknown at the moment

Materials and Methods

We retrospectively reviewed the medical records of domestic animals admitted with snakebites to the Veterinary Hospital of Tras-os-Montes and Alto Douro (Vila Real, Portugal), Santa Marinha Veterinary Clinic (Avanca, Portugal) and Calweton Veterinary Group (United Kingdom) from 2020 to 2023. This study included animals in which two fang marks were observed at the wound site, or the tutors were witnesses of the attack.

With the cases presented, the authors aim to help improve the knowledge regarding snakebites in Europe.





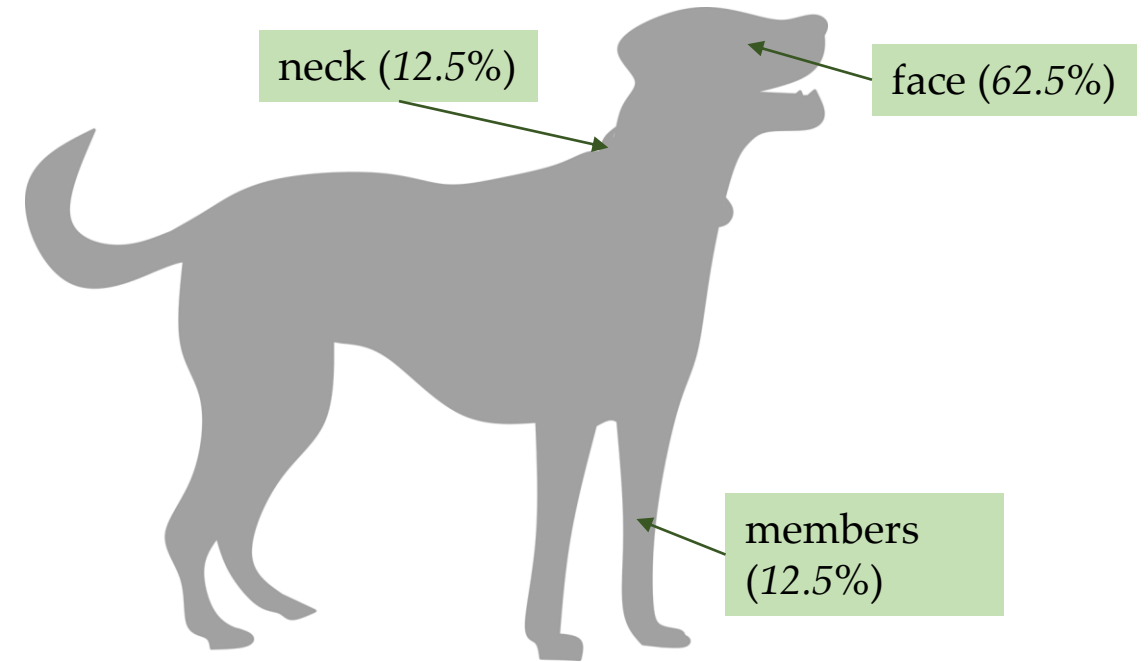
Results

This study involved a total of 8 animals from Portugal and the United Kingdom, that included 1 feline, 2 goats and 6 canids.

The dogs represented 4 breeds including Labrador Retriever (1), Whippet (1), Springer Spaniel English (2), and Collie (1).

The cat was mixed breed. Overall, 20%(1) of dogs were males, and 80% (4) were females. The cat was a male (1). The goats both were females (2).

The age of the animals was between 3 and 12 years.



Location of the bite wounds.

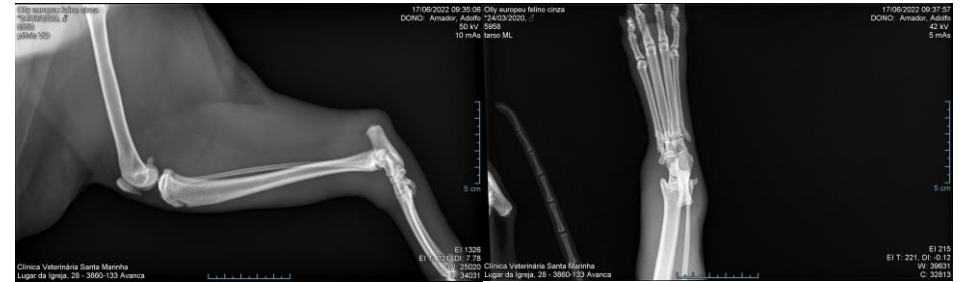The clinical signs observed on presentation in all cases were oedema and erythema. All the dogs survive. The cat and the goats did no survive. Only two animals were administrated antivenom, the remaining animals were treated with a support treatment.



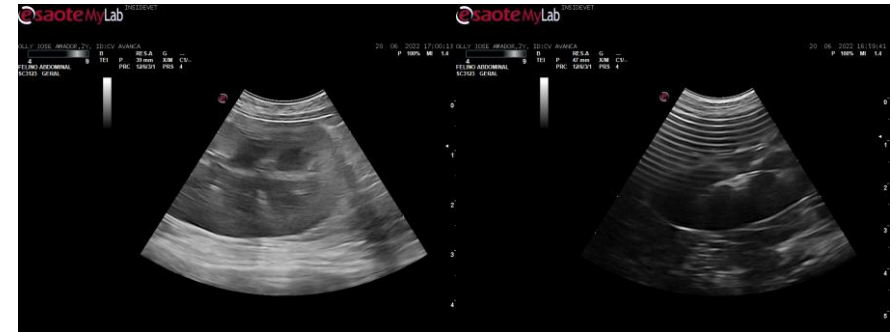Results

Case 1: Feline, neutered male, 3 years old

According to the tutors, the animal was absent for a day and when it returned, it staggered again, with anorexia and very prostrate. On physical examination, the temperature was 41.7°C, and the right hind limb was edematous, especially in the tarsal area, painful to the touch and without support. The animal was hospitalized and treated with IV fluids and antibiotic therapy. After 24h, a hematoma begins to form on the inner thigh, with a small area of skin in the centre starting to necrose. After 3 days the temperature returned to normal values, but the necrotic lesion continued to progress and generalized edema throughout the body was observed. Transfusion of fresh frozen plasma was performed on the 6th day of hospitalization, as he had hypoalbuminemia, but he did not show improvement and died after 2 days. Necropsy was not performed



Radiography of the right hind limb of a male cat 12h after a snake bite.



Abdominal echography with hypoechoic pancreas and slight generalized peritoneal reaction in cat bitten by a venomous snake.

Parameter	Reference values	17/06/2022	23/06/2022
Albumin	2.3-3.5 g/dl	3.0	1.1
Urea	17.6-32.8 mg/dl	40	2
Creatinine	0.8-1.8 mg/dl	2.64	1.03
Alkaline phosphatase (FA)	11-67 U/l	19	
Alanine Aminotransferase (ALT)	18-77 U/l	162	
Glucose	71-148 mg/dl	99	
Total Protein (TP)s	5.7-7.8 g/dl	6.7	

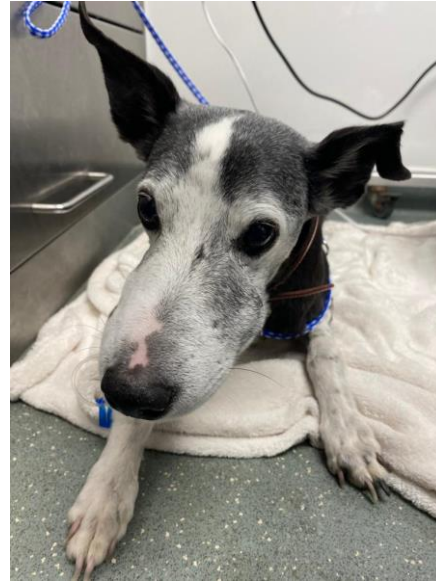

Results

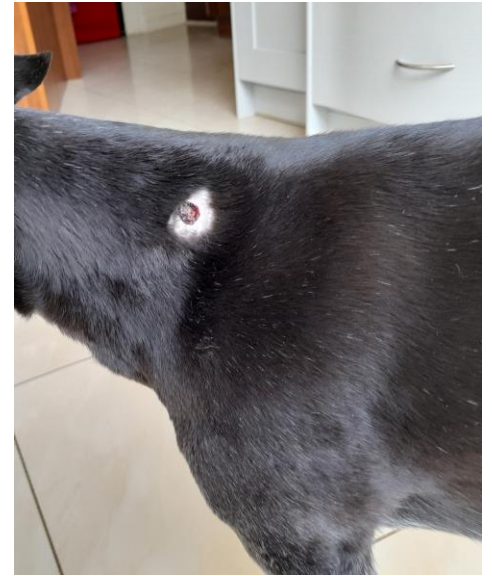Case 2 - Canine, Whippet, neut female, 4 years

The tutors did not see the viper (*Vipera berus*) but there were plenty in the area around. After the animal had been sniffing the grass the animal become lethargic, head down, and started swelling around the mouth/face.

On physical exam it was panting, temperature 38.3°C, swelled around the mouth that went towards the ventral head, painful at the touch that not allowed head manipulation. Admitted and placed on IV fluids, with meloxicam, chlorpheniramine and buprenorphine, a fan was also placed to help to cool down. Swelling progressed to the axilla region and paracetamol was added to the treatment. The animal did not eat, she conyined treatment with IV fluids, Piriton; Dexadreson, Synulox, Prevomax and omeprazole. The animal fully recovered.



Oedema of the face and mouth in a female dog bitten by a venomous snack.



Possible snake bite wound in a dog.

Parameter	Reference values	
Amylase (AMY)	200.0-1200.0 U/L	1542
Glucose (GLU)	3.3-6.1 mmol/L	6.4
Total Protein (PT)	54-82 g/L	47
Globulin (GLOB)	23-52 g/L	16
Microhaematocrit (PCV)	37-55%	48

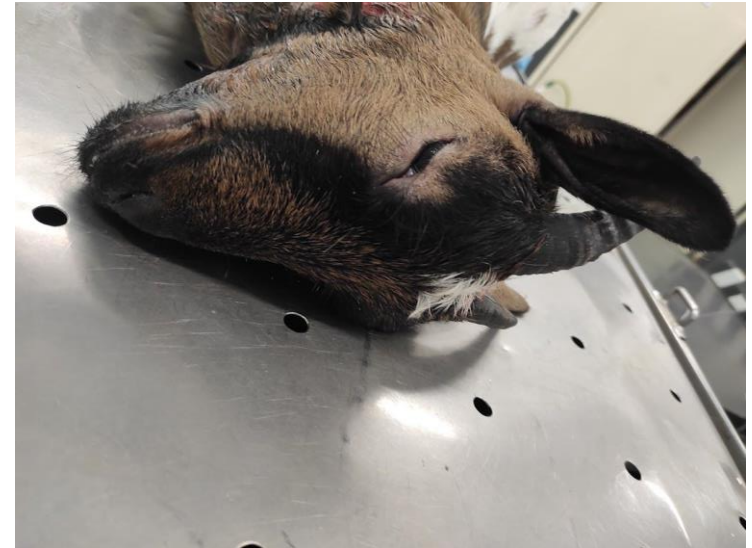Valours from the biochemical parameter after 24h snake bite.



Results

Case 3: Small ruminant, Autochthonous Bravia Goats, female, adult, age indeterminate

Two animals presented lethargy, head down, and oedema of the face. It was observed bit marks on the face and neck. In the region where this animal lived, the most probable responsible for the bit were *Malpolon monspessulanus*, *Macroprotodon brevis* or *Vipera latastei*. Both animals died before initiating treatment due to oedema of the glottis.



Conclusions

The present study has several limitations owing to its retrospective design. The medical records were occasionally incomplete because data from three different animal hospitals were collected for analysis due to the low incidence of snakebites in animals in Portugal. The majority of the cases occurred in the UK. Although snakebites in small animals in some regions of Europe are an uncommon medical problem, they should be considered as they can eventually lead to death, as observed in one case. In the future, more studies are necessary to help a better triage and treatment of animal victims of snake bites.





References

1. Kim, D.; Kim, S.; Kim, J.-K.; Lim, J.H.; Choi, G.; Bae, S.; Kwon, Y.-S.; Jang, M. Clinical Features and Management of Snake Bites in 70 Dogs in Korea. *J Vet Sci* **2022**, *23*, e81, doi:10.4142/jvs.22105.
2. Paro, B. The 11 VENOMOUS SNAKES Found in Europe! (ID Guide). *Bird Watching HQ*.
3. Cabral, M.; Almeida, J.; Almeida, P.; Dellinger, T.; Ferrand de Almeida, M.; Oliveira, M.; Palmeirim, J.; Queirós, A.; Rogado, L.; Santos-Reis, M. *Livro Vermelho Dos Vertebrados de Portugal*; Instituto da Conservação da Natureza: Lisboa, 2005;
4. The IUCN Red List of Threatened Species Available online: <https://www.iucnredlist.org/es> (accessed on 4 February 2022).
5. Palci, A.; LeBlanc, A.R.H.; Panagiotopoulou, O.; Cleuren, S.G.C.; Mehari Abraha, H.; Hutchinson, M.N.; Evans, A.R.; Caldwell, M.W.; Lee, M.S.Y. Plicidentine and the Repeated Origins of Snake Venom Fangs. *Proceedings of the Royal Society B: Biological Sciences* **2021**, *288*, 20211391, doi:10.1098/rspb.2021.1391.
6. *Handbook of Venoms and Toxins of Reptiles*; Mackessy, S.P., Ed.; 2nd ed.; CRC Press: Boca Raton, 2021; ISBN 978-0-429-05420-4.
7. Martín, C.; Nogué, S. [Changes in viper bite poisonings]. *Med Clin (Barc)* **2015**, *144*, 132–136, doi:10.1016/j.medcli.2014.06.015.
8. Gilliam, L.L.; Brunker, J. North American Snake Envenomation in the Dog and Cat. *Vet Clin North Am Small Anim Pract* **2011**, *41*, 1239–1259, doi:10.1016/j.cvsm.2011.08.008.
9. Bolon, I.; Babo Martins, S.; Ochoa, C.; Alcoba, G.; Herrera, M.; Bofia Boyogueno, H.M.; Sharma, B.K.; Subedi, M.; Shah, B.; Wanda, F.; et al. What Is the Impact of Snakebite Envenoming on Domestic Animals? A Nation-Wide Community-Based Study in Nepal and Cameroon. *Toxicon: X* **2021**, *9–10*, 100068, doi:10.1016/j.toxcx.2021.100068.
10. Bolton, F.M.S.; Casewell, N.R.; Al-Abdulla, I.; Landon, J. Production and Assessment of Ovine Antisera for the Manufacture of a Veterinary Adder Antivenom. *Vet Rec* **2014**, *174*, 406, doi:10.1136/vr.102286.
11. Bolon, I.; Finat, M.; Herrera, M.; Nickerson, A.; Grace, D.; Schütte, S.; Babo Martins, S.; Ruiz de Castañeda, R. Snakebite in Domestic Animals: First Global Scoping Review. *Preventive Veterinary Medicine* **2019**, *170*, 104729, doi:10.1016/j.prevetmed.2019.104729.
12. Aroch, I.; Harrus, S. Retrospective Study of the Epidemiological, Clinical, Haematological and Biochemical Findings in 109 Dogs Poisoned by *Vipera Xanthina* *Palestinae*. *Vet Rec* **1999**, *144*, 532–535, doi:10.1136/vr.144.19.532.
13. Segev, G.; Shipov, A.; Klement, E.; Harrus, S.; Kass, P.; Aroch, I. *Vipera Palaestinae* Envenomation in 327 Dogs: A Retrospective Cohort Study and Analysis of Risk Factors for Mortality. *Toxicon* **2004**, *43*, 691–699, doi:10.1016/j.toxicon.2004.03.001.
14. Armentano, R.A.; Schaer, M. Overview and Controversies in the Medical Management of Pit Viper Envenomation in the Dog. *J Vet Emerg Crit Care (San Antonio)* **2011**, *21*, 461–470, doi:10.1111/j.1476-4431.2011.00677.x.