

TOXOPLASMA GONDII AS A CAUSE OF MULTI-
ORGAN DISORDERS IN THE CAT'S BODY

Gavrilova N.A., Samoilova D.S.

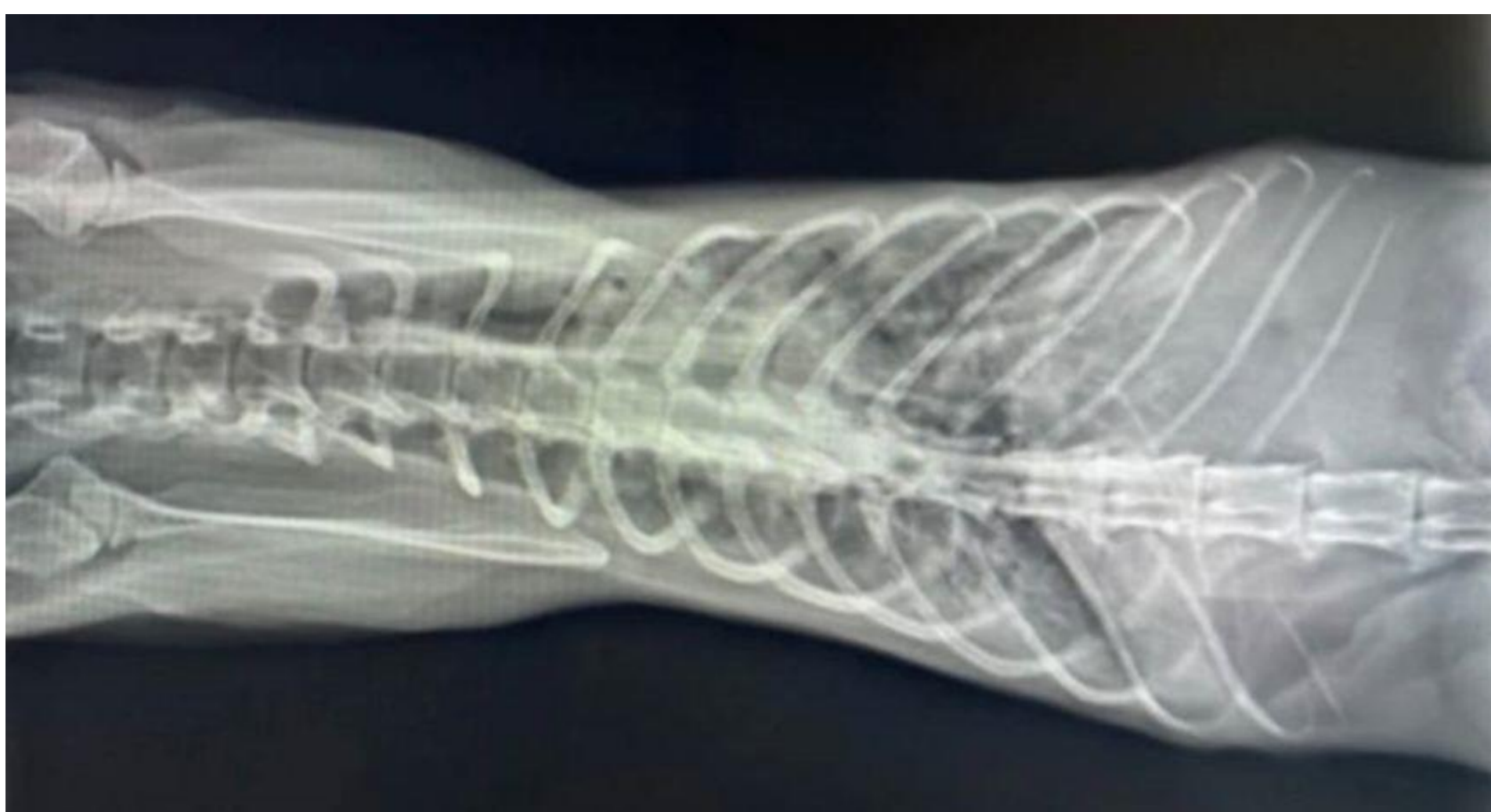Federal State Budgetary Educational Institution of Higher Education
"St. Petersburg State University of Veterinary Medicine",
St. Petersburg, Russia

INTRODUCTION & AIM

Toxoplasmosis is an acute, subacute, chronic and asymptomatic zoonotic protozoal disease caused by the intracellular parasite *Toxoplasma gondii*. It is characterized in intermediate hosts, which are more than 400 species of mammals, including humans, by abortions, birth of non-viable young with various deformities, damage to the nervous system, visual organs, lymphatic and endocrine systems. In definitive hosts, which are many species of the Felidae family, including *Felis catus* (domestic cat) - damage of intestinal epithelial cells and accompanied by functional disorders of the digestive system.

Toxoplasmosis in animals remains an urgent and significant problem requiring timely diagnosis and a set of therapeutic and prophylactic measures. According to a number of researchers, the epizootic situation remains difficult, as in a number of countries in Europe, South America and the USA from 9 to 46% of cats have a positive reaction in serologic tests for toxoplasmosis. Studies conducted in the Russian Federation revealed infestation in 34.9% of the cats examined. High intensity of infestation was found in large cities: 32% of cats were infected in Kazan, 16 to 24.1% in Vologda, and 33.8% in Moscow

MATERIALS & METHOD'S



A 6-year-old cat was admitted to the veterinary center of St. Petersburg with the following clinical signs: hyporexia, hyperthermia, breathing difficulties, cough, and diarrhea. FIV (feline immunodeficiency virus) was previously diagnosed in this animal. The cat's living condition is apartment. The cat was fed with dry food. From the anamnesis it was noted that the cat ate a bird that flew into the house. Clinical examination included examination, ultrasound and radiologic examination, clinical and biochemical blood tests, cytologic examination of bronchoalveolar mucus and peritoneal fluid, as well as PCR blood test for detection of antibodies to *T. gondii* pathogen.

RESULTS & DISCUSSION

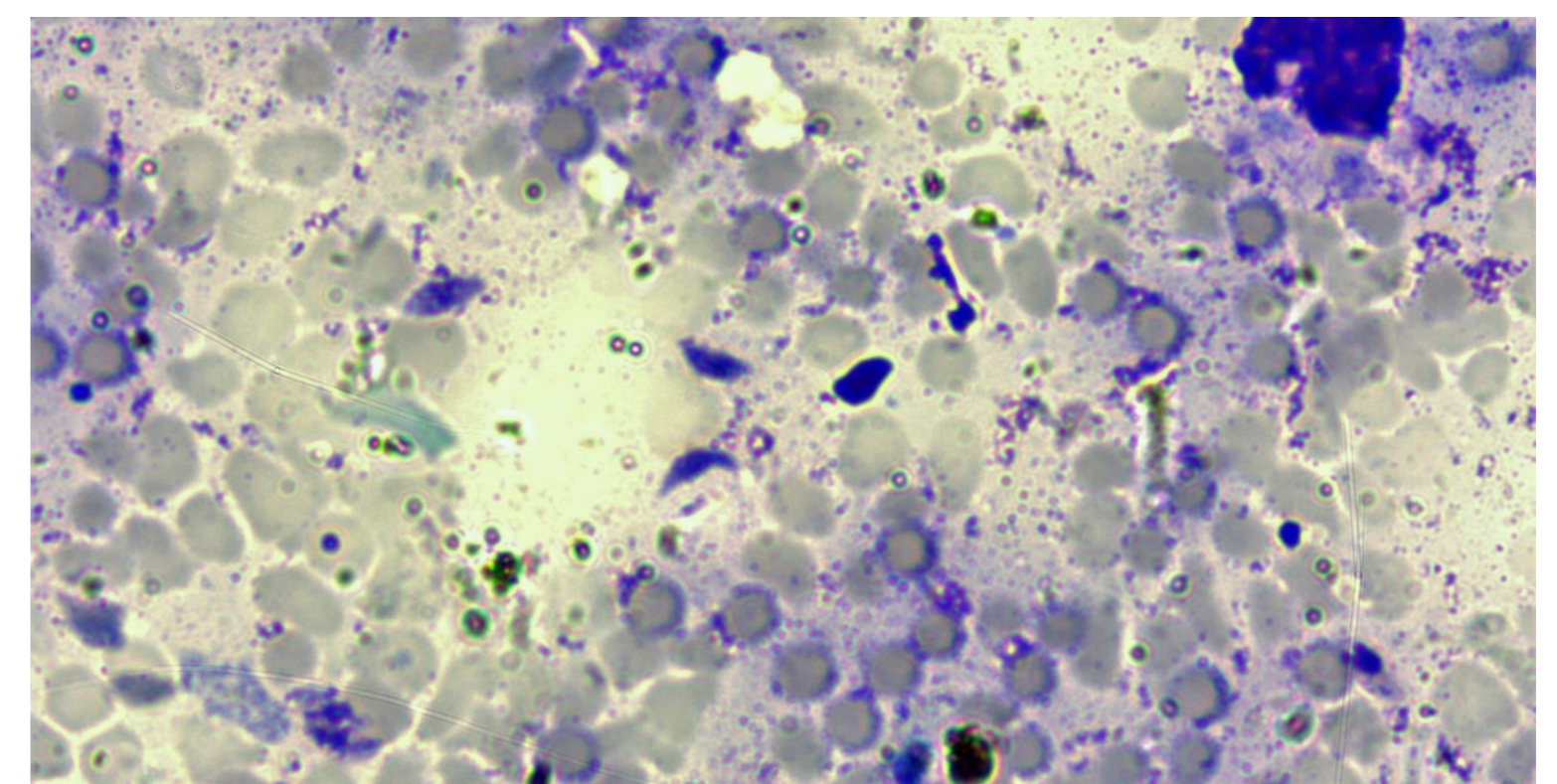
Examination of the cat revealed jaundice of the mucous membranes. Palpation revealed painfulness in the area of the stomach and liver. Ultrasound examination revealed decreased intestinal peristalsis, enlarged mesenteric lymph nodes, hepatomegaly, hyperemia, edema of gastric and small intestinal mucosa.

Radiologically, multiple small nodules were found in the lungs, having a patchy, and in some places a confluent character of distribution. Pathologic foci were distributed bilaterally, asymmetrically, mainly in the lower parts of the lungs

According to blood test results, hyperbilirubinemia (13.2 $\mu\text{mol/L}$) and marked thrombocytopenia (74.0) were noted.

DNA fragments belonging to *T. gondii* were identified by real-time PCR. Cytologic examination of bronchoalveolar mucus and peritoneal fluid revealed *T. gondii* trophozoites

If a cat with reduced immune status shows such clinical signs as: enlarged lymph nodes, lethargy, decreased appetite, weight loss, nasal discharge, cough, intestinal disorders, the diagnosis of toxoplasmosis should be confirmed or excluded by serologic, PCR or ELISA tests. Cumulative failure of several functional systems, developing as a terminal stage of the acute course of toxoplasmosis, can be fatal.



CONCLUSION

When the animal is kept in an apartment, its infestation with *T. gondii* cannot be excluded. The entrance gate of the parasite is most often the digestive organs. In this case, the pathogen got into the cat's organism probably due to eating a bird with *T. gondii* trophozoites in its organs and tissues.

FUTURE WORK / REFERENCES

The paper analyzes a clinical case of toxoplasmosis in a cat with multiorgan failure. A 6-year-old domestic cat was admitted to the veterinary center of St. Petersburg. Earlier the animal was diagnosed with feline immunodeficiency virus (FIV - feline immunodeficiency virus). Hyporexia, oppression, hyperthermia, breathing difficulties, coughing and diarrhea began to appear after the cat had caught and eaten a bird that had flown into the living space a month earlier. Biochemical analysis in the animal's blood revealed hyperbilirubinemia (13.2 $\mu\text{mmol/L}$) and thrombocytopenia (74.0). Ultrasound examination revealed decreased intestinal peristalsis, enlarged mesenteric lymph nodes, hepatomegaly, hyperemia, and edema of gastric and small intestinal mucosa. Radiologically, multiple small nodules were found in the lungs, having a patchy, and in some places a confluent character of distribution. Pathologic foci were distributed bilaterally, asymmetrically, mainly in the lower parts of the lungs. Cytologic examination of bronchoalveolar mucus and peritoneal fluid revealed trophozoites of *Toxoplasma gondii*.

DNA fragments belonging to *T. gondii* were identified by real-time PCR. Etiotropic and symptomatic therapy applied to the cat in the in-patient conditions of the veterinary clinic was unsuccessful. Toxoplasmosis in animals with reduced immune status can lead to serious systemic disorders, including lesions of the digestive and respiratory systems, liver and other organs. Cumulative failure of several functional systems, developing as a terminal stage of the acute course of toxoplasmosis, can be fatal.