

**Accelerated recovery from facial paralysis using individual-target transcranial magnetic stimulation after masseteric-facial nerve end-to-end anastomosis**Shun Qi<sup>1,2</sup>, Yang Rao<sup>2</sup>, Chuanzhu Sun<sup>2</sup>, Zhou Fei<sup>3</sup>, Sanzhong Li<sup>3</sup>

1 The Key Laboratory of Biomedical Information Engineering of Ministry of Education, Institute of Health and Rehabilitation Science, School of Life Science and Technology, Xi'an Jiaotong University, The Key Laboratory of Neuro-informatics &amp; Rehabilitation Engineering of Ministry of Civil Affairs, Xi'an, Shaanxi, P.R.China

2 Shaanxi Brain Modulation and Scientific Research Center, Xi'an, Shaanxi, P.R.China

3 Department of Neurosurgery, the 1st Affiliated Hospital of Air Force Medical University, Xi'an, Shaanxi, P.R.China

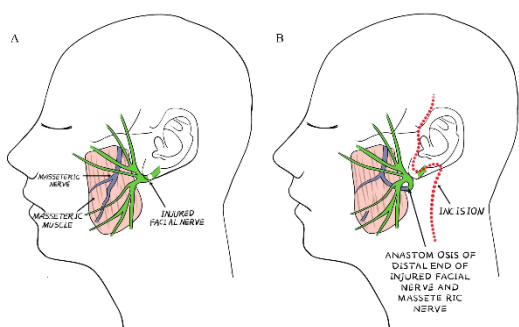
E-mail address: sunny\_3c@126.com

**Background:** The resection of intracranial tumors in cerebellopontine angle area such as acoustic neuroma often causes facial paralysis. The injury of Facial Nerve is the immediate cause. Nerve anastomosis, including end-to-end and side-to-end hypoglossal-facial nerve anastomosis (HFA) and masseteric-facial nerve anastomosis (MFA), is an effective method to remodel injured nerve and establish nerve regeneration pathway. However, end-to-end MFA needs more than 12 months to regain a normal facial function and good symmetry. Repetitive transcranial magnetic stimulation (rTMS) applies continuously adjustable magnetic field to achieve cumulative currents. However, whether rTMS can be used in promoting facial recovery from paralysis in patients after MFA remains to be explored.

**Methods:** Individual-target TMS (IT-TMS) was performed using a stimulator with a figure-of-8 coil and a neuronavigational system, the Black Dolphin Navigation Robot that guided the targeting over the specific anatomical sites corresponding to facial and masseteric muscles in precentral gyrus (Brodmann area 4) across different sessions. 10 Hz stimulation delivering 18 trains with an intertrain interval of 8 seconds (1800 pulses per session, 2 sessions/3600 pulses per day, 5 days/10 sessions per week, 1 week interval after 1 week stimulation) was conducted. The intensity was set at 120% of the resting motor threshold. The intersession interval was 50 min, and the treatment lasts 6 months. House-Brackmann scale was performed.

**Result:** The accelerated recovery from facial paralysis with a novel form of rTMS, IT-TMS, was confirmed.

**Conclusion:** IT-TMS could be a promising effective neurostimulation for patients after MFA who will commonly go through a longer period of rehabilitation.

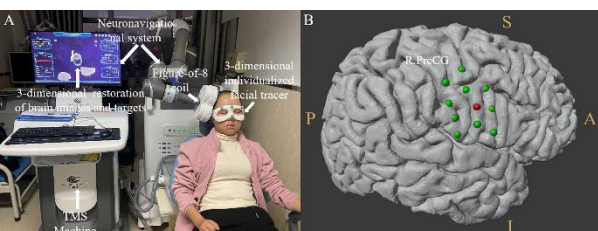


**FIGURE 1:** Drawing of masseteric-facial nerve anastomosis. (A) The relative position of facial nerve and masseteric nerve anatomically on paralyzed side was identified; (B) Masseteric nerve was cut off from one of the distal end and anastomosed with the main trunk of the extracranial facial nerve.

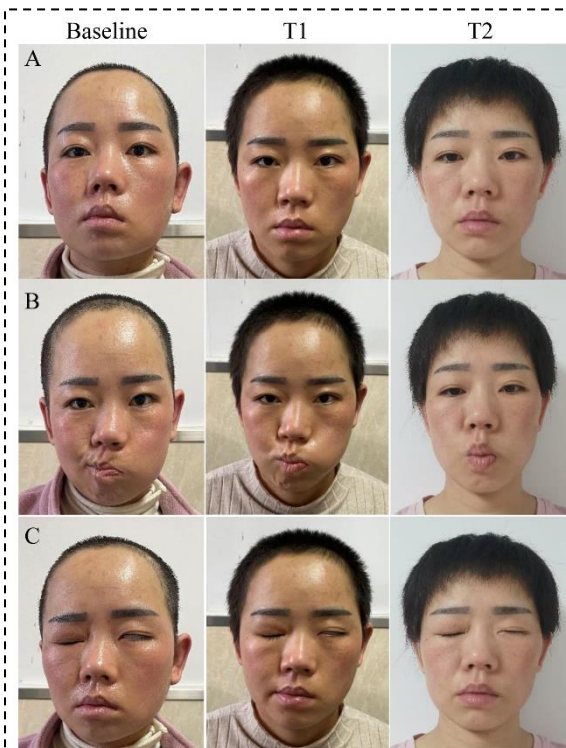**The results of modified House-Brackmann facial grading scale**

Time point <sup>a</sup>	modified House-Brackmann facial grading scale system <sup>a</sup>				Total score <sup>a</sup>	Grade <sup>a</sup>	p value <sup>a</sup>
	Eyebrow <sup>a</sup>	Eye <sup>a</sup>	Nasolabial fold <sup>a</sup>	Oral <sup>a</sup>			
Baseline <sup>a</sup>	6 <sup>a</sup>	6 <sup>a</sup>	6 <sup>a</sup>	6 <sup>a</sup>	24 <sup>a</sup>	VI <sup>a</sup>	N/A <sup>a</sup>
T1 <sup>a</sup>	6 <sup>a</sup>	5 <sup>a</sup>	6 <sup>a</sup>	5 <sup>a</sup>	22 <sup>a</sup>	V <sup>a</sup>	0.646 <sup>N.S.</sup> <sup>a</sup>
T2 <sup>a</sup>	2 <sup>a</sup>	2 <sup>a</sup>	1 <sup>a</sup>	1 <sup>a</sup>	6 <sup>a</sup>	II <sup>a</sup>	0.002 <sup>**</sup> /0.028 <sup>#</sup> <sup>a</sup>

Abbreviation: N/A, not applicable; N.S., not significant. Baseline: before IT-TMS treatment; T1: after the first 1-month treatment; T2: six months later. Comparisons were made by one-way analysis of variance; <sup>N.S.</sup> indicates no significant difference between T1 and Baseline and  $p$  value > 0.05; <sup>\*\*</sup> indicates the significant difference between T2 and Baseline and  $p$  value < 0.01; <sup>#</sup> indicates the significant difference between T2 and T1 and  $p$  value < 0.05<sup>†</sup>.



**FIGURE 2:** (A) IT-TMS: experimental set-up with labeled devices; (B) Green dots indicate the representative sites corresponding to masseteric muscles, among which the masseteric hotspot is shown in red. (C) Schematic diagram shows the signal evoked by the stimulation coil proceeds from masseteric muscle representation target (red dot) located in precentral gyrus of Brodmann 4 area to masseteric nerve through fasciculi (yellow tracts), ultimately arriving at facial nerve.



**FIGURE 3:** Static (A), dynamic (B) and eye closure (C) images of the face at baseline, 1 month later (T1), 6 months later (T2) after the initiation of IT-TMS.

**Acknowledgement**  
This work was supported by Academic Discipline Boosting Program of Xijing Hospital (grant number XJZT19ML13).

**References**

- Samii M, Matthies C. Management of 1000 vestibular schwannomas (acoustic neuromas): the facial nerve-preservation and restitution of function. *Neurosurgery*. 1997;40(4):684-695.
- Yawn RJ, Wright HV, Francis DO, Stephan S, Bennett ML. Facial nerve repair after operative injury: Impact of timing on hypoglossal-facial nerve graft outcomes. *American Journal of Otolaryngology*. 2016;37(6):493-496.
- Chen G, Wang W, Wang W, Ding W, Yang X. Symmetry Restoration at Rest after Masseter-to-Facial Nerve Transfer: Is It as Efficient as Smile Reanimation? *Plastic and Reconstructive Surgery*. 2017;140(4):793-801.
- Bitter T, Sorger B, Hesselmann V, Krug B, Lackner K, Guntinas-Lichius O. Cortical representation sites of mimic movements after facial nerve reconstruction: A functional magnetic resonance imaging study. *Laryngoscope*. 2011;121(4):699-706.
- Donzelli R, Maiuri F, Peca C, Cavallo LM, Motta G, de Divitiis E. Microsurgical repair of the facial nerve. *Neurochirurgia*. 2006;52(1):69-70.
- Biglioli F, Colombo V, Rabbiosi D, et al. Masseteric-facial nerve neurohaphy: results of a case series. *Journal of Neurosurgery*. 2017;126(1):312-318.
- Wassermann EM. Risk and safety of repetitive transcranial magnetic stimulation: report and suggested guidelines from the International Workshop on the Safety of Repetitive Transcranial Magnetic Stimulation. *Electroencephalography Clinical Neurophysiology/ Evoked Potentials Section*. 1998;108(1):1-16.
- Yildiz S, Bademkiran F, Yildiz N, Aydogdu I, Uludag B, Ertekin C. Facial motor cortex plasticity in patients with unilateral peripheral facial paralysis. *NeuroRehabilitation*. 2007;22(2):133-140.