

# Facial and Smile symmetry: Customized Iris Positioning Device for Enhancing the Realism of Ocular Prostheses<sup>†</sup>

Shyla Dureja <sup>1</sup>, Raghavendra Swamy <sup>2</sup>, Srinivasa Iyer Meenakshi <sup>3</sup> \* , Ganesh Somashekara Char <sup>4</sup>, Rocco Franco<sup>5</sup>, Vincenzo Ronsivalle<sup>6</sup> and Maria Maddalena Marrapodi<sup>7</sup>

- <sup>1</sup> Post Graduate Student (MDS), Department of Prosthodontics, JSS Dental College and Hospital, Bannimantap, Mysuru, Karnataka- 570015, India. shyla.dureja@gmail.com (SD)
- <sup>2</sup> Professor and HOD, Department of Prosthodontics, JSS Dental College and Hospital, Bannimantap, Mysuru, Karnataka- 570015, India. dr.raghavendraswamykn@jssuni.edu.in (RS)
- <sup>3</sup> Assistant Professor, Department of Prosthodontics, JSS Dental College and Hospital, Bannimantap, Mysuru, Karnataka- 570015, India. dr.meenakshis@jssuni.edu.in (SIM)
- <sup>4</sup> Reader, Department of Prosthodontics, JSS Dental College and Hospital, Bannimantap, Mysuru, Karnataka- 570015, India. dr.sganesh@jssuni.edu.in (GSC)
- <sup>5</sup> Department of Biomedicine and Prevention, University of Rome "Tor Vergata", 00100 Rome, Italy; rocco.franco@ptvonline.it (RF)
- <sup>6</sup> Department of Biomedical and Surgical and Biomedical Sciences, Catania University, 95123 Catania, Italy; Vincenzo.ronsivalle@hotmail.it (VR)
- <sup>7</sup> Department of Woman, Child and General and Specialist Surgery, University of Campania "Luigi Vanvitelli", 80121 Naples, Italy; mariamaddalena.marrapodi@studenti.unicampania.it (MMM)
- \* Correspondence: mariamaddalena.marrapodi@studenti.unicampania.it (MMM); dr.meenakshis@jssuni.edu.in (SIM)
- <sup>†</sup> Presented at the 4th International Electronic Conference on Applied Sciences; Available online: <https://asec2023.sciforum.net/>.

**Abstract:** The eyes, being one of the most prominent facial features, play a crucial role in facial symmetry and are subject to extensive scrutiny in terms of their morphological and functional aspects. Numerous studies have explored the association between facial symmetry and the morphology of the eyes. Symmetrical faces are generally perceived as more attractive and are believed to indicate good genetic health. As a result, research has focused on the measurements of ocular symmetry, including inter-eye distance, eye shape, and eyelid symmetry. It has been found that individuals with more symmetrical eyes are often perceived as more attractive and exhibit enhanced social desirability. The eyes play a crucial role in facial expression and are vital sensory organs. A 49-year-old patient presented with a chief complaint of facial disfigurement due to shrunken right eyelids resulting from trauma-related evisceration. Diagnosis: Trauma-related evisceration. Various techniques for iris positioning have been reported in the literature, but they have had limitations. This clinical report presents an improved and effective technique utilizing a Customized Iris Positioning Device, consisting of a transparent graph sheet attached to a forehead clip. Outcome: The customized ocular prosthesis significantly improved the patient's quality of life and restored her self-confidence. The Customized Iris Positioning Device offered enhanced proximity to the eye and provided several advantages, including accurate pupil centralization, customization, re-verification, and being cost effective.

**Keywords:** Custom made; Ocular prosthesis; Evisceration; Iris Positioning; Graph Grid

**Citation:** To be added by editorial staff during production.

Academic Editor: Firstname Last-name

Published: date



**Copyright:** © 2023 by the authors. Submitted for possible open access publication under the terms and conditions of the Creative Commons Attribution (CC BY) license (<https://creativecommons.org/licenses/by/4.0/>).

## 1. Introduction

The eye, being one of the most vital sense organs, is the central focus of facial expression, and pinnacle of aesthetic beauty. Eye loss is typically associated with congenital defects, disfiguring painful blind eye, trauma (accidents, perforation), tumours (melanoma, retinoblastoma, metastasis), glaucoma, and sympathetic ophthalmia [1]. An orbital

evisceration, enucleation, or exenteration may be necessary as a surgical intervention for these conditions [2].

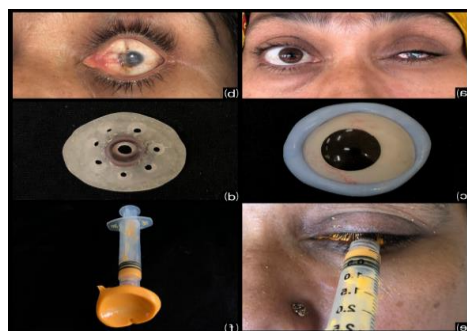
With context to dentistry, the Iris Positioning Device aligns with the principles of comprehensive dental rehabilitation, where the restoration of facial aesthetics and function is of paramount importance [3–6].

The management of anophthalmia sockets from a dental clinician's perspective presents a significant challenge, primarily due to cicatricial retraction resulting from atrophy and tissue modifications. This complex condition necessitates careful consideration of the prosthesis dimensions and contour to achieve optimal outcomes in terms of realistic appearance and symmetry [7,8]. The inclusion of an artificial iris in the ocular prosthesis is crucial to enhance the natural-appearing gaze of the patient, particularly in cases where the defect involves the eyes and orbital contents, leading to significant facial disfigurement.

This clinical report demonstrates the technique to fabricate a customized ocular prosthesis using a Customized iris positioning device for a patient with a history of trauma-related evisceration.

## 2. Methods

A 49-year-old female patient presented to the Department of Prosthodontics with the chief complaint of shrunken right eyelids causing facial disfigurement. History revealed a road traffic accident causing injury to the right eye. Surgical evisceration was performed along with the placement of a spherical implant and a conformer 5 weeks ago. Clinical examination revealed a healthy intraocular tissue bed, with sufficient depth beneath the fornices for prosthetic retention (Figure 1).

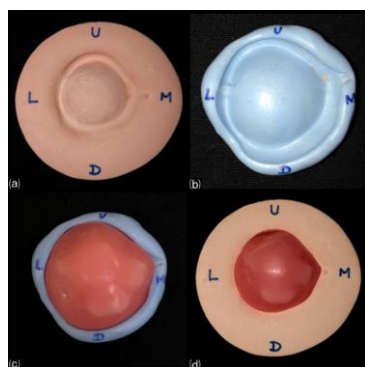


**Figure 1.** (a) Patient post evisceration, (b) Close-up view of the right eye socket, (c) Putty impression of the intaglio surface of the stock ocular prosthesis, (d) Custom tray with needle hub and perforations, (e) Impression made using light body addition silicone, (f) Final impression in light body addition silicone.

## 3. Results and Discussion

Patients can wear ocular prostheses with increased comfort and a better appearance because to new materials and better-fitting devices. An ocular prosthesis, sometimes known as a fake eye, substitutes the missing organ and gives the patient psychological and esthetical satisfaction. It is typically made of polymethyl methacrylate (PMMA) or acrylic resin. The use of an appropriate-contour, size, and color ocular prosthesis prevents patients from becoming disabled and allows them to lead normal lives. The ocular prosthesis can be produced to order or prefabricated. The latter offers patients greater comfort, a better fit for the eye socket, and superior cosmetic effects. The custom prosthesis can be created using traditional methods or with the use of digital technologies. In the traditional method, the base shell is made after the ocular defect has been imprinted, cured, and manually stained to match the patient's natural eye. The foundation shell can be 3D printed using digital technology, and digital photos can help with and print stains. A putty consistency of polyvinyl addition silicone impression material (Aquasil, Dentsply, Germany)

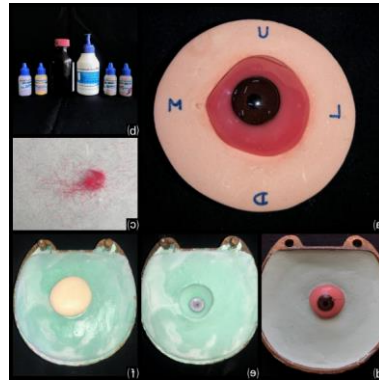
was used to make a template of the intaglio surface of the patient's stock ocular prosthesis, which was further used for fabrication of the custom tray. The self-cure polymethyl methacrylate custom tray's borders were relieved by 2mm, and multiple perforations were made to remove surplus impression material. A syringe hub was attached utilising cyanoacrylate to the large central perforation to allow the attachment of the syringe. (Figure 1). A thin layer of Vaseline was applied to the patient's eye socket. Light body polyvinyl addition silicone impression material (Reprosil, Dentsply, Germany) was loaded into the syringe and attached to the custom tray hub, which was already in the eye. The functional impression was made by slowly injecting the material into the patient's eye socket, while instructing her to move the eye to the right, left, up and down, and subsequently in a circular motion. (Figure 1). The impression was poured in Die Stone (Kalrock, Kalabhai, India). A putty index of the intaglio surface of the final impression was made for easy removal of wax conformer during fabrication owing to its flexibility. Hard wax (Cavex, Netherland) was poured into the putty index. Its adaptation was cross verified in the master cast (Figure 2). The anterior surface of the wax conformer was sculpted to mimic the characteristics of the contra-lateral natural eye. The wax conformer's try-in was performed and checked for size, comfort, aesthetics, eyelid support and simulation of eye movement. A Castroviejo Calliper was used to measure the iris and pupil diameter of the contralateral normal eye. A stock ocular prosthesis with the same precise measurements and colour as the contralateral normal eye was chosen. A Customized iris positioning device was made using a forehead clip and a customised transparent graph sheet. The forehead clip was made from the retaining bar of a file holder. The transparent graph sheet was customised according to the patient's facial contours with a precise triangular opening for the nose. The whole assembly was stabilised on the forehead using an elastic strand. The facial midline was transferred to the forehead clip for repositioning the device. The medial, distal, superior, and inferior extremities of the iris of the natural eye were established as vertical and horizontal lines on the device. Using the grids in the graph and vernier calliper measurements, the exact position of the pupil was determined using the natural eye as a reference. This was followed by the placement of the iris button in the wax conformer with the necessary contouring. The iris position was reverified using a Customized Iris Positioning Device. The wax pattern was invested using Dental Stone (Kalstone, Kalabhai, India) into the first pour in a three-piece flask. A 19-gauge wire was attached to the iris, which helped to properly orient the iris after the dewaxing procedure.



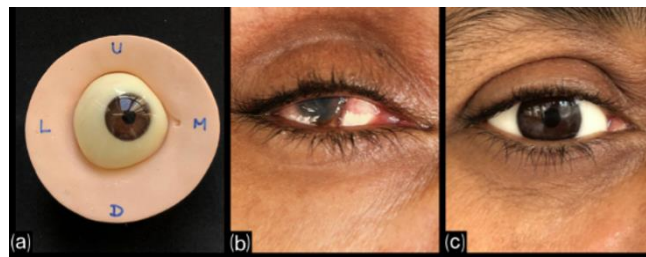
**Figure 2.** (a) Master cast in die stone, (b) Putty index of final impression for easy retrieval of the wax conformer, (c) Wax conformer fabrication in the putty index, (d) Wax conformer verification in master cast.

Tooth Coloured Heat Cure Material (DPI, Dental products of India) was used for the final processing. Heat Cure Pigments and rayon thread fibrils were added to simulate accurate shade matching and vasculature (Figure 3). After conventional acrylization, the custom-fabricated ocular prosthesis was trimmed, smoothed, and polished to get a natural glossy finish. The ocular prosthesis was positioned in the socket and assessed for fit,

support, aesthetics, and coordination with the contralateral eye (Figure 4). The patient was advised to wipe the tissue bed once a day with a wet gauze piece and to rinse the prosthesis once a day with water and soap. For lubrication, the patient was advised to use carboxymethylcellulose sodium 0.5 % eye drops artificial tear solution once a day [9–11]. The patient reviewed on days 1, 2, and 7 following prosthetic insertion. A six-month follow-up was performed for prosthesis evaluation. (Figure 4).



**Figure 3.** (a) Wax conformer on the master cast, (b) Tooth Coloured Heat Cured PMMA along with Heat Cure Pigments, (c) Rayon fibrils, (d) 19 Gauge wire attached to iris to prevent displacement, (e) Dewaxing, (f) Packing.



**Figure 4.** (a) Customised Eye Prosthesis, (b) Pre-Treatment close-up view, (c) Post-Treatment close-up view.

Customizing the iris requires additional time, skill, and precision from the operator. Various methods and techniques for determining iris positioning are documented in the literature. These include Pupillometer, Facial measurements, Visual Assessment, Inverted anatomic tracings, Ocular locator, Graph grid, Boleys gauge, Pupillary distance ruler, Digital photography, and Electronic vernier calliper [9,12–15]. All these methods had minor inaccuracies in precise pupil centralization which were mitigated using the Customised Iris positioning device. Numerous techniques have been developed over the years for iris positioning in prosthetic eyes to achieve optimal esthetics and functional outcomes [16–18]. The continuous advancements in iris positioning techniques reflect the commitment of prosthodontists to achieve precise and aesthetically pleasing outcomes in the fabrication of prosthetic eyes. Using the Customised iris positioning device, a new technique for iris positioning was performed. This method's benefits included patient-specific customization and stability. The customized nasal contour aperture allowed proximity of the device to the eye thus resulting in precise pupil centralization[19,20]. There was no requirement for an assistant to hold the device. The re-verification of markings could be performed at every step, and it could also be given to the patient. The facial midline and natural iris extremities may be challenging to precisely mark in cases of facial asymmetry, but the device grid lines will serve as a guide. This method was simple, precise, and cost-effective, one that could be performed single-handedly in a clinical setting.

#### 4. Conclusion

This case report underscores the importance of studying these interrelated features from both scientific and clinical perspectives to gain deeper insights into human aesthetics, evolution, and health. Therefore, this case report aims to demonstrate that custom eye prostheses best restore facial symmetry and mimicry, giving the patient greater comfort and a better social life.

**Supplementary Materials:** Not Applicable

**Author Contributions:** Conceptualization, SS and RS; methodology, SIM; software, GSC; validation, SD, GSC and RS; formal analysis, RS; investigation, SD; resources, SD; data curation, RS; writing—original draft preparation, RF; writing—review and editing, VR; visualization, RF; supervision, MMM; project administration, SD; funding acquisition, SD. All authors have read and agreed to the published version of the manuscript.

**Funding:** Not applicable

**Institutional Review Board Statement:** Not applicable

**Informed Consent Statement:** The authors certify that they have obtained all appropriate patient consent forms. In the form, the patient(s) has/have given his/her/their consent for his/her/their images and other clinical information to be reported in the journal. The patients understand that their names and initials will not be published, and due efforts will be made to conceal their identity, but anonymity cannot be guaranteed.

**Data Availability Statement:** Not applicable

**Acknowledgments:** Not applicable

**Conflicts of Interest:** The authors declare no conflict of interest

## References

1. Ababneh, O.H.; Abotaleb, E.A.; Abu Ameerh, M.A.; Yousef, Y.A. Enucleation and Evisceration at a Tertiary Care Hospital in a Developing Country. *BMC Ophthalmol* **2015**, *15*, 1–7, doi:10.1186/s12886-015-0108-x.
2. K, H.; SR, S.; R, R.; Nair, V. v; Janardanan, K. Fabrication of Custom -Made Ocular Prosthesis Using a Graph Grid. *International Journal of Applied Dental Sciences* **2021**, *7*, 145–147, doi:10.22271/oral.2021.v7.i1c.1128.
3. Shah, F.; Aeran, H. Prosthetic Management of Ocular Defect: Esthetics for Social Acceptance. *The Journal of Indian Prosthodontic Society* **2008**, *8*, 66, doi:10.4103/0972-4052.43588.
4. Minervini, G.; Franco, R.; Marrapodi, M.M.; Crimi, S.; Badnjević, A.; Cervino, G.; Bianchi, A.; Cicciù, M. Correlation between Temporomandibular Disorders (TMD) and Posture Evaluated Through the Diagnostic Criteria for Temporomandibular Disorders (DC/TMD): A Systematic Review with Meta-Analysis. *J Clin Med* **2023**, *12*, 2652, doi:10.3390/jcm12072652.
5. Minervini, G.; Franco, R.; Marrapodi, M.M.; Fiorillo, L.; Cervino, G.; Cicciù, M. Post-traumatic Stress, Prevalence of Temporomandibular Disorders in War Veterans: Systematic Review with Meta-analysis. *J Oral Rehabil* **2023**, doi:10.1111/joor.13535.
6. Minervini, G.; Franco, R.; Marrapodi, M.M.; Fiorillo, L.; Cervino, G.; Cicciù, M. Economic Inequalities and Temporomandibular Disorders: A Systematic Review with Meta-analysis. *J Oral Rehabil* **2023**, *50*, 715–723, doi:10.1111/joor.13491.
7. Nimonkar, S.; Belkhode, V.; Sathe, S.; Borle, A. Prosthetic Rehabilitation for Hemimaxillectomy. *Journal of Datta Meghe Institute of Medical Sciences University* **2019**, *14*, 99, doi:10.4103/jdmimsu.jdmimsu\_40\_19.
8. Inchingolo, F.; Tatullo, M.; Abenavoli, F.M.; Marrelli, M.; Inchingolo, A.D.; Gentile, M.; Inchingolo, A.M.; Dipalma, G. Non-Syndromic Multiple Supernumerary Teeth in a Family Unit with a Normal Karyotype: Case Report. *Int J Med Sci* **2010**, 378–384, doi:10.7150/ijms.7.378.
9. Guttal, S.S.; Patil, N.P.; Vernekar, N.; Porwal, A. A Simple Method of Positioning the Iris Disk on a Custom-Made Ocular Prosthesis. A Clinical Report. *Journal of Prosthodontics* **2008**, *17*, 223–227, doi:10.1111/j.1532-849X.2007.00272.x.

10. Putanikar, N.Y.; Patil, A.G.; Shetty, P.K.; Nagaral, S.; Mithaiwala, H.I. Prosthetic Rehabilitation of a Patient with Ocular Defect Using Semi-Customized Prosthesis: A Case Report. *J Int Oral Health* **2015**, *7*, 81–84.
11. Kavlekar, A.A.; Aras, M.A.; Chitre, V. An Innovative and Simple Approach to Fabricate a Hollow Ocular Prosthesis with Functional Lubricant Reservoir: A Solution to Artificial Eye Comfort. *Journal of Indian Prosthodontist Society* **2017**, *17*, 196–202, doi:10.4103/0972-4052.194946.
12. Dr. Nidhi Dinesh Sinha, Dr. Aruna J Bhandari, Dr.S.A.G. Fabrication of Custom Ocular Prosthesis Using a Graph Grid. *Pravara Med Rev* **2009**, *1*, 22–24, doi:10.22271/oral.2021.v7.i1c.1128.
13. K, H.; SR, S.; R, R.; Nair, V. v; Janardanan, K. Fabrication of Custom -Made Ocular Prosthesis Using a Graph Grid. *International Journal of Applied Dental Sciences* **2021**, *7*, 145–147, doi:10.22271/oral.2021.v7.i1c.1128.
14. Sathe, S.; Pisulkar, S.; Nimonkar, S.V.; Belkhode, V.; Borle, A. Positioning of Iris in an Ocular Prosthesis: A Systematic Review. *J Indian Prosthodont Soc* **2020**, *20*, 345–352, doi:10.4103/jips.jips\_374\_19.
15. Bhochhibhoya, A.; Mishra, S.; Mathema, S.; Acharya, B.; Maskey, B. Alternative Technique of Iris Orientation in a Custom-Made Ocular Prosthesis. *Journal of Prosthodontics* **2019**, *28*, 601–604, doi:10.1111/jopr.12687.
16. Qamar, Z.; Alghamdi, A.M.S.; Haydarah, N.K. Bin; Balateef, A.A.; Alamoudi, A.A.; Abumismar, M.A.; Shivakumar, S.; Cicciù, M.; Minervini, G. Impact of Temporomandibular Disorders on Oral Health-related Quality of Life: A Systematic Review and Meta-analysis. *J Oral Rehabil* **2023**, doi:10.1111/joor.13472.
17. Minervini, G.; Franco, R.; Marrapodi, M.M.; Fiorillo, L.; Cervino, G.; Cicciù, M. Prevalence of Temporomandibular Disorders ( <scp>TMD</Scp> ) in Pregnancy: A Systematic Review with Meta-analysis. *J Oral Rehabil* **2023**, doi:10.1111/joor.13458.
18. Minervini, G.; Franco, R.; Marrapodi, M.M.; Ronsivalle, V.; Shapira, I.; Cicciù, M. Prevalence of Temporomandibular Disorders in Subjects Affected by Parkinson Disease: A Systematic Review and Metanalysis. *J Oral Rehabil* **2023**, doi:10.1111/joor.13496.
19. Sabbatini, M.; Santillo, M.; Pisani, A.; Paternò, R.; Uccello, F.; Serù, R.; Matrone, G.; Spagnuolo, G.; Andreucci, M.; Serio, V.; et al. Inhibition of Ras/ERK1/2 Signaling Protects against Postischemic Renal Injury. *American Journal of Physiology-Renal Physiology* **2006**, *290*, F1408–F1415, doi:10.1152/ajprenal.00304.2005.
20. Spagnuolo, G.; Annunziata, M.; Rengo, S. Cytotoxicity and Oxidative Stress Caused by Dental Adhesive Systems Cured with Halogen and LED Lights. *Clin Oral Investig* **2004**, *8*, doi:10.1007/s00784-003-0247-y.