

Retrorectal Hamartoma Presenting as a Presacral Mass: Surgical Management and Diagnostic Challenges

Luciano Ferrando · Marina Manzanera Díaz · Adel Eldabe · Felipe Reoyo Pascual · Miguel Ángel Álvarez Rico

Department of General and Digestive Surgery, Hospital Universitario de Burgos, Burgos, Spain.

INTRODUCTION

Retrorectal tumors are rare lesions that arise in the presacral space and include a heterogeneous group of congenital, inflammatory, and neoplastic entities.

Among them, retrorectal hamartomas, also known as tailgut cysts, are uncommon congenital lesions originating from remnants of the embryonic hindgut.

Their clinical presentation is often nonspecific, which frequently delays diagnosis and complicates management.

MATERIALS AND METHODS

We report the case of a patient diagnosed with a retrorectal mass detected during imaging evaluation for nonspecific pelvic symptoms.

Radiological assessment with pelvic magnetic resonance imaging demonstrated a well-defined presacral lesion located posterior to the rectum. The patient underwent elective surgical resection through a posterior approach. Intraoperative findings, surgical technique, and postoperative outcomes were analysed.

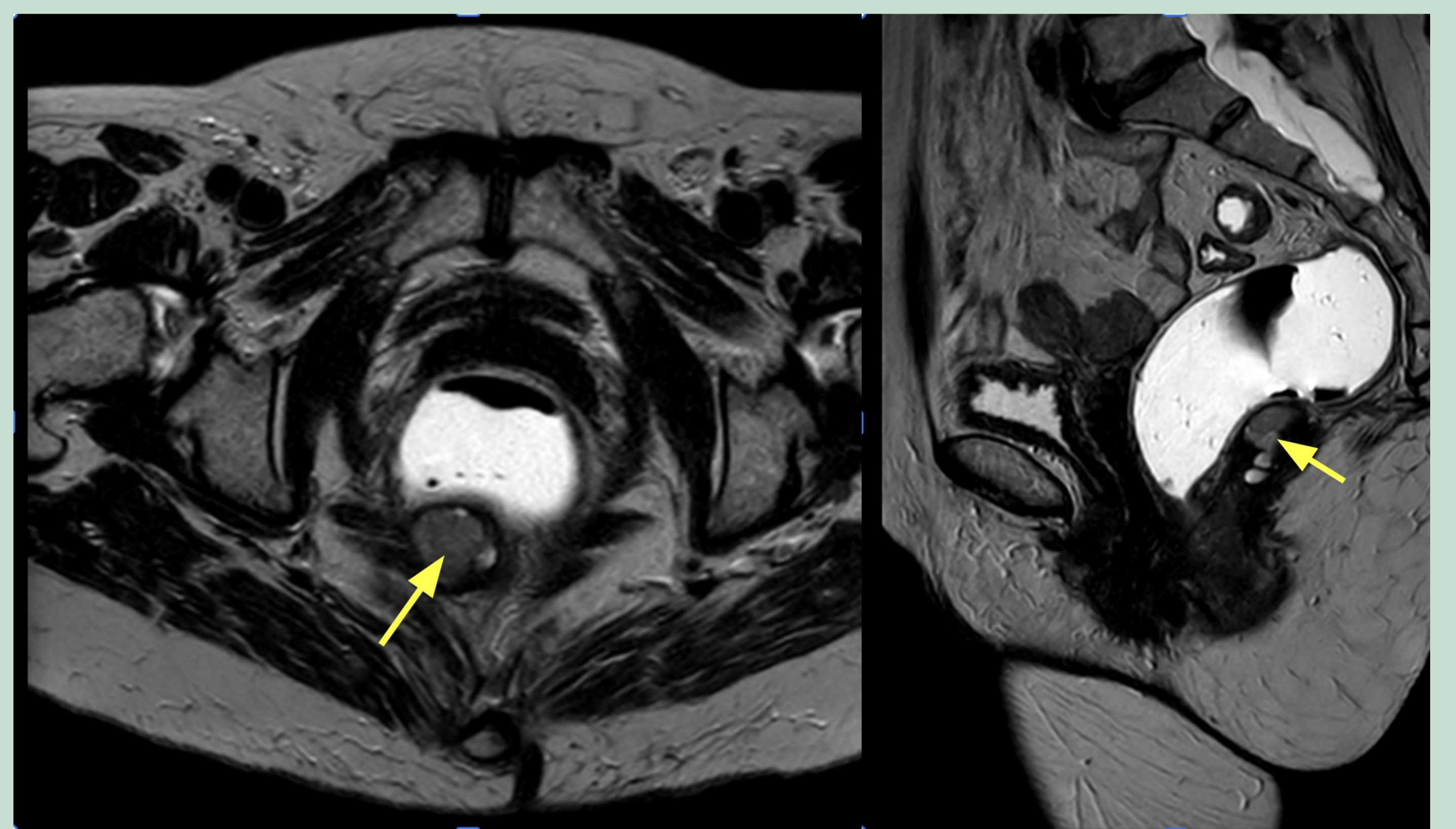
RESULTS

Complete excision of the presacral mass was achieved without intraoperative complications.

The lesion was carefully dissected from surrounding structures within the confined retrorectal space.

Histopathological examination confirmed the diagnosis of a retrorectal hamartoma.

The postoperative course was uneventful, and the patient remained asymptomatic during follow-up.



CONCLUSIONS

Retrorectal hamartomas are rare congenital lesions that may present as presacral masses with nonspecific clinical manifestations. Accurate radiological evaluation and complete surgical excision are essential for definitive diagnosis and management. Awareness of these uncommon entities is important for surgeons managing presacral lesions in order to ensure appropriate treatment and avoid potential complications.

