

Neisseria macacae isolated in a patient's peritoneal dialysate effluent

Eugene Y.H. Yeung ^{1,2,3}

Affiliations: 1. Faculty of Medicine, University of British Columbia; 2. Faculty of Pharmaceutical Sciences, University of British Columbia; 3. School of Medicine, Simon Fraser University

INTRODUCTION & AIM

- *Neisseria macacae* is a gram-negative diplococcus colonized in the oral cavity of monkeys.
- Finding *N. macacae* in patients' specimens may cause suspicion of patients' exposure to monkeys.
- We encountered a case of *N. macacae* isolated in a patient's peritoneal dialysate effluent that demonstrated how the *Neisseria* taxonomy can be misleading.

METHOD

- This 31-year-old male is a previous anabolic steroid user who was diagnosed to have end-stage renal disease secondary to biopsy proven focal segmental glomerulosclerosis.
- Fifty days after his peritoneal dialysis catheter insertion, he complained of one-day history of cloudy dialysate effluent, which was sent for laboratory analysis.
- The effluent's total nucleated count (TNC) was $13504 \times 10^6/L$, with 0.97 neutrophil and 0.03 monocyte/macrophage.
- The effluent was inoculated in an aerobic blood culture bottle which showed growth after 30 hours of incubation.
- Gram stain of the culture fluid showed moderate polymorphonuclear leukocytes in addition to gram negative diplococci in 1000x magnification (**Figure 1**).
- He received one intraperitoneal dose of ceftazidime 1.5 g and vancomycin 2 g.

RESULTS & DISCUSSION

- After 24-hour incubation, this microorganism was identified as *Neisseria macacae* by matrix-assisted laser desorption/ionization time-of-flight (MALDI-TOF) mass spectrometry (score > 2.0).
- Subsequently, 16S ribosomal RNA testing identified this microorganism as *Neisseria macacae/perflava*.
- *N. macacae/perflava* are usually non-pathogenic commensal flora in oropharynx of rhesus macaques.
- However, the patient denied exposure to monkeys.
- A review of the Bruker manufacturer MALDI-TOF library showed limitations in differentiating between *Neisseria macacae* and *Neisseria sicca*, a commensal flora.
- In three days, his dialysate effluent TNC decreased to $93 \times 10^6/L$.
- He subsequently received 18 intraperitoneal doses of ceftriaxone 1 g daily and clinically improved.

CONCLUSION

- This case demonstrated the importance of clinical correlation in interpreting test results and diagnosing zoonotic diseases.

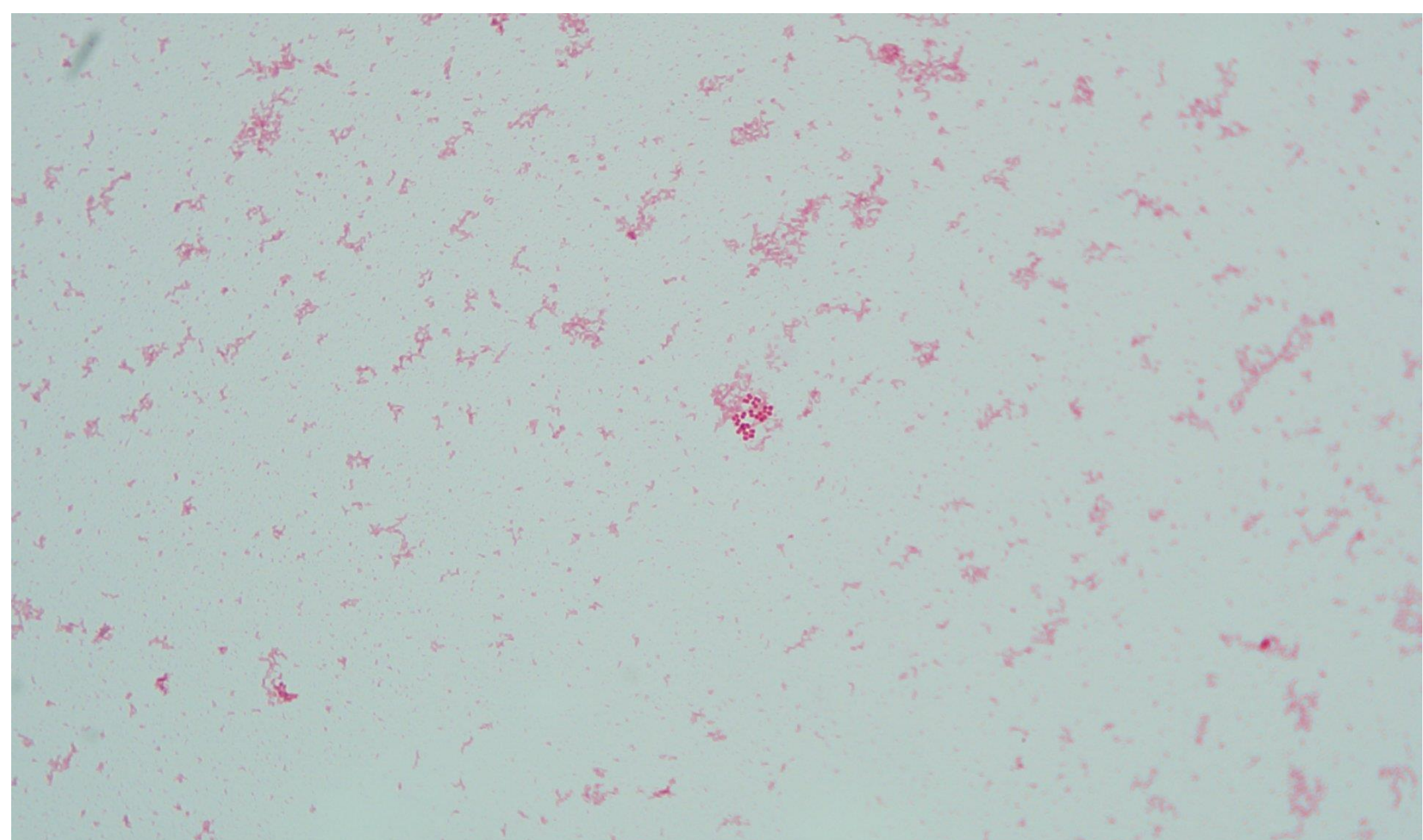


Figure 1: Gram stain of the culture of patient's dialysate effluent fluid showed gram negative diplococci in 1000x magnification