

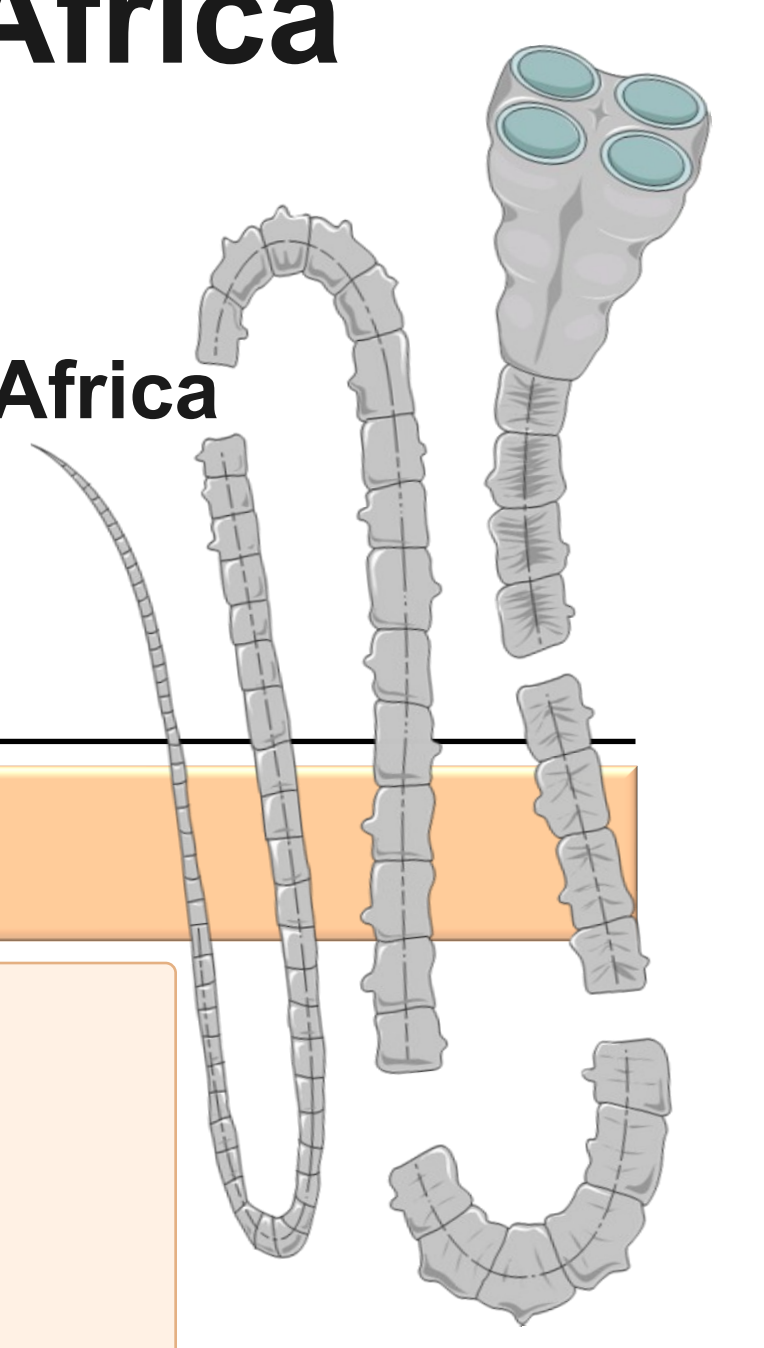
Prevalence of Taeniosis among humans in Mpumalanga Province, South Africa

Ilze du Plooy^{1,2}, Riann Christian¹, Malitaba Mlangeni¹, Ana M. Tsotetsi-Khambule¹

1. Department of Life and Consumer Sciences, College of Agriculture and Environmental Sciences, University of South Africa

2. Department of Microbiology, Ampath National Reference Laboratory, Centurion, South Africa

Correspondence: dp.ilze@gmail.com SciProfile: <https://sciprofiles.com/profile/IlzeduPlooy>



INTRODUCTION & AIM

Taeniosis is a parasitic disease caused by the adult stage of the zoonotic cestode, *Taenia* spp. Humans become infected by eating raw/undercooked beef or pork contaminated with *Taenia saginata* or *T. solium* cysticerci, respectively.

Taeniosis is often mild or asymptomatic, however *T. solium* carriers are important since the ingestion of eggs can cause cysticercosis, including neurocysticercosis. Infection of livestock can lead to major economic losses through the downgrading of cysticerci-infected meat. In South Africa, taeniosis is not mandatorily reportable and human prevalence data remain limited.

Research objective

To determine the prevalence of taeniosis in humans from Mpumalanga Province, South Africa.

METHOD



Routine laboratory stool samples

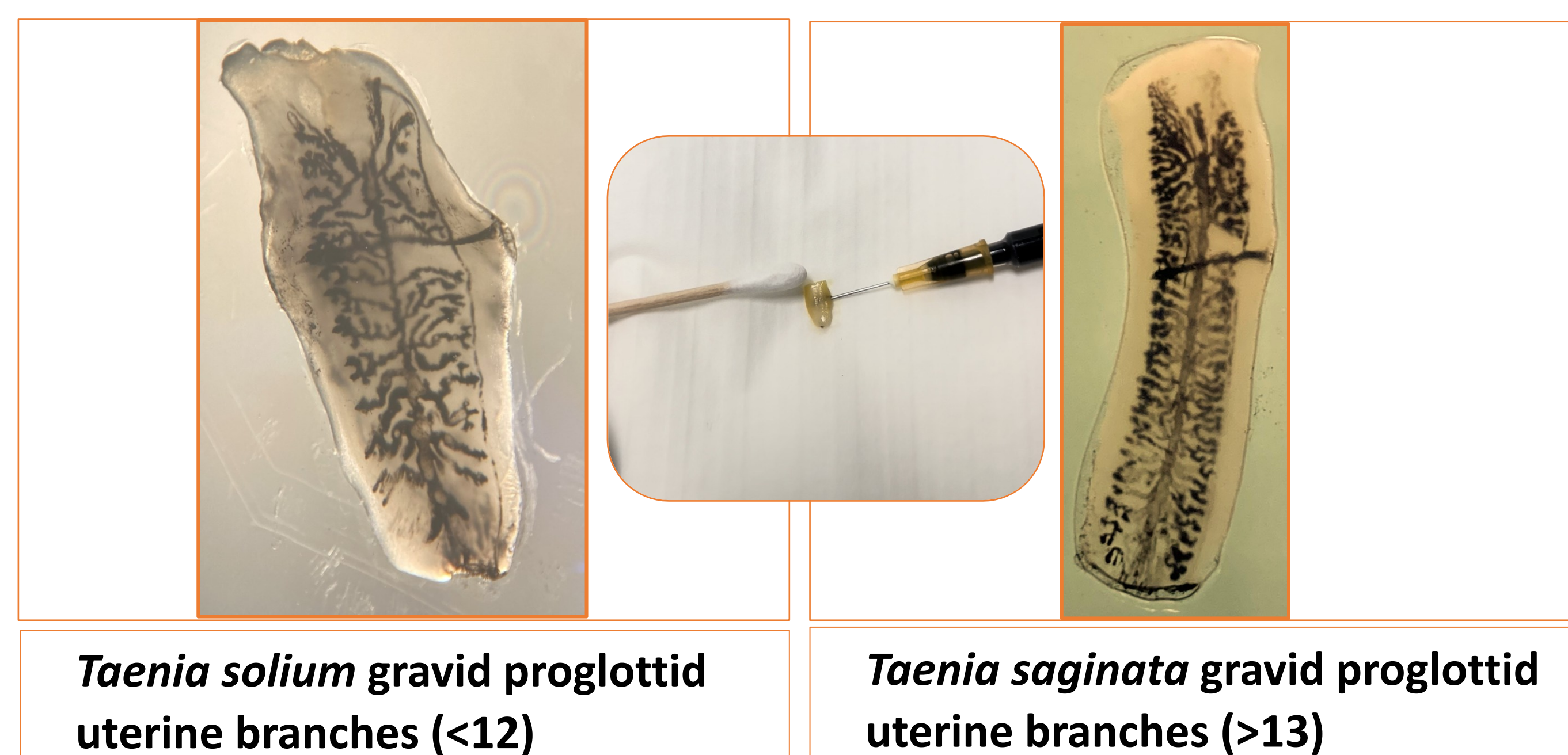


Macroscopy for *Taenia* spp proglottids



Microscopy for *Taenia* spp ova

Routine laboratory-submitted stool samples from adults in Mpumalanga province were collected from a private laboratory. Demographic data, including age, gender and location were recorded. Stool aliquots were frozen at -20 °C for molecular analysis later. The remaining stool was preserved in 10% formal saline and stored at 2-8 °C until microscopy. Samples were examined for the presence of *Taenia* spp proglottids. The proglottids were injected with India ink to visualize the primary lateral uterine branches. In literature, there is an overlap on the number of main branches and the species. A cut-off was established, where <12 primary lateral branches would indicate *T. solium* and >13 primary lateral branches would indicate *T. saginata*. The presence of ova in microscopy was recorded as *Taenia* spp. Data was analysed and converted into tables and maps.



Taenia solium gravid proglottid uterine branches (<12)

Taenia saginata gravid proglottid uterine branches (>13)

Fig. 1. Visualization of the primary lateral uterine branches of *Taenia* proglottids. India ink was injected into the uterine opening with a fine needle and syringe. The proglottid was then squashed between two microscope slides. The primary uterine branches were counted unilaterally with the aid of a stereo microscope.

RESULTS & DISCUSSION

250 of 400 samples tested thus far
5 Positive samples (*Taenia saginata*)
2% preliminary prevalence in sample group

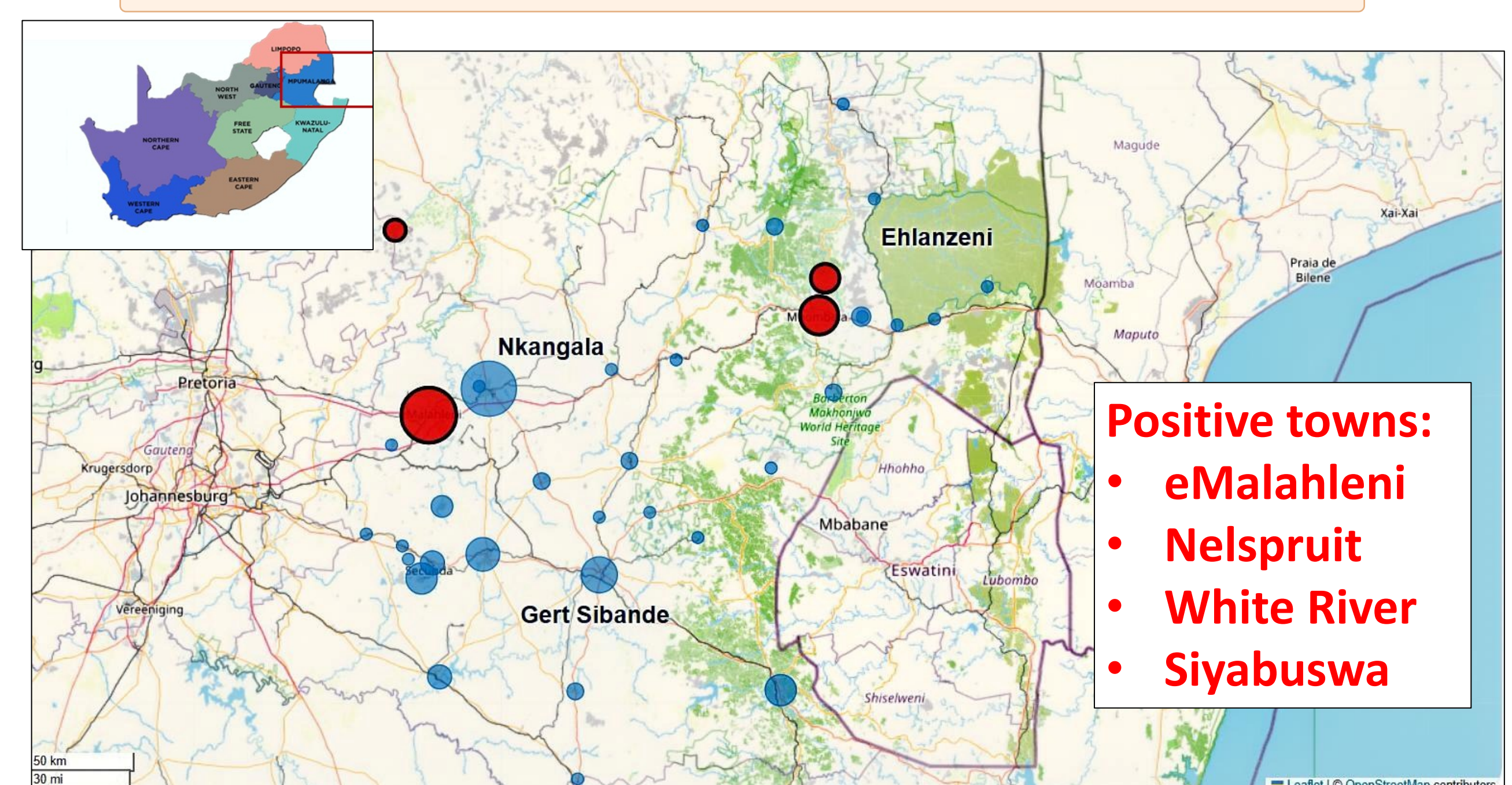


Fig. 2. Distribution of samples in Mpumalanga, South Africa

Positive samples (red); Negative samples (blue).

Bubble size indicates number of samples.

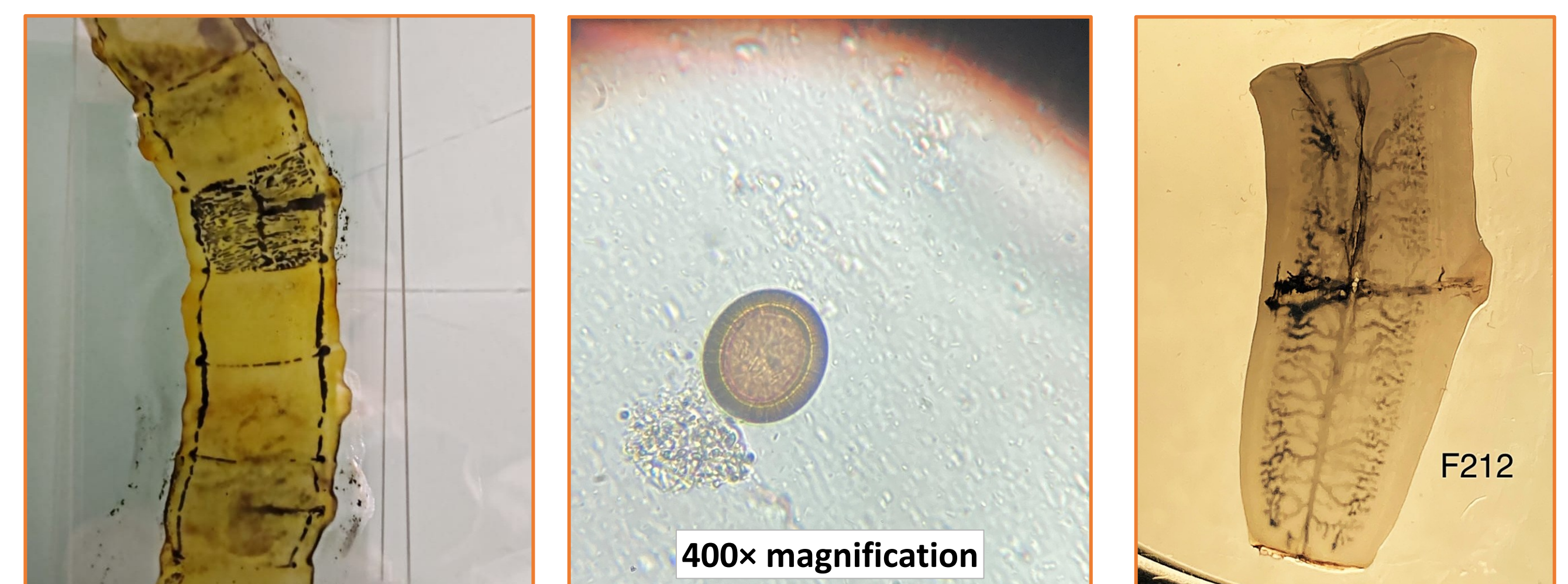


Fig. 3. Proglottids and *Taenia* ova observed in positive samples.

A total of 250 stool samples had been examined at the time of data analysis. Five samples were positive for taeniosis, giving a preliminary prevalence of 2%. Positive samples originated from Nkangala and Ehlanzeni districts. All proglottids from the positive samples were morphologically identified as *T. saginata*. The current prevalence falls within the range of 0.78% and 3.8% reported in previous South African stool-based studies.

CONCLUSION

Taeniosis is present in the sampled adult population from Mpumalanga Province, with preliminary findings indicating *T. saginata* infection. These results highlight the need for continued surveillance. Taeniosis is often underreported and may indicate environmental contamination and food-safety gaps relevant to both human and animal health.

FUTURE WORK / REFERENCES

Future work will consist of sample testing, demographic analysis and spatial mapping. Molecular tests will be used to confirm *Taenia* spp DNA and genotyping of positive samples will be performed.

- Dermauw, V., Dorny, P., Braae, U. C., Devleeschauwer, B., Robertson, L. J., Saratsis, A., & Thomas, L. F. (2018). Epidemiology of *Taenia saginata* taeniosis/cysticercosis: a systematic review of the distribution in southern and eastern Africa. *Parasites & Vectors*, 11(1), 578. <https://doi.org/10.1186/s13071-018-3163-3>
- Ifeoma, A., Apalata, T., Aviwe, B., Oladimeji, O., & Abaver, D. T. (2022). Prevalence of Intestinal Parasites in HIV/AIDS-Infected Patients Attending Clinics in Selected Areas of the Eastern Cape. *Microbiology Research*, 13(3), 574-583. <https://doi.org/10.3390/microbiolres13030040>
- Kwitshana, Z. L., Tsoka, J. M., & Mabaso, M. L. H. (2008). Intestinal parasitic infections in adult patients in KwaZulu-Natal. *SAMJ: South African Medical Journal*, 98(9), 709-711. Retrieved June 24, 2025, from http://www.scielo.org.za/scielo.php?script=sci_arttext&pid=S0256-95742008000900018&lng=en&tng=en.
- Mpaka-Mbatha, M., Naidoo, P., Islam, M., Singh, R., & Mkhize-Kwitshana, Z. (2023). Demographic profile of HIV and helminth-coinfected adults in KwaZulu-Natal, South Africa. *Southern African Journal of Infectious Diseases*, 38(1), 7 pages. [doi:https://doi.org/10.4102/sajid.v38i1.466](https://doi.org/10.4102/sajid.v38i1.466)
- Okello, A. L., & Thomas, L. F. (2017). Human taeniasis: current insights into prevention and management strategies in endemic countries. *Risk Management and Healthcare Policy*, 10, 107-116. <https://doi.org/10.2147/RMHP.S116545>