



COENUROSIS AN EMERGING DISEASE IN WILD RABBITS

Valladares-Carranza B^{1*}; Zamora-Espinosa JL¹; Velázquez-Ordoñez V¹; Ortega-Santana C¹;
Felipe-Pérez YE¹

¹Facultad de Medicina Veterinaria y Zootecnia. Universidad Autónoma del Estado de México. Toluca, México.

*Corresponding author: benvac2004@yahoo.com.mx.

Tel.: 01 (722) 2 96 55 55, 2 96 89 80.

Received: / Accepted: / Published:

Abstract: The emerging diseases in the different animal species require the necessary attention, to carry out actions that diminish their diffusion in animal populations. The aim of this study is to provide a current reference on coenurosis a wild rabbit (hare), and determinants of its presentation on animal health, which can put at risk man's health. A sample of muscle tissue was evaluated and a hydatid cyst (3 x 6 cm) was obtained from a wild rabbit. The tissue was punctured, extracting transparent aqueous liquid discarding an abscess or hematoma. Content analysis showed the presence of many scolices, corresponding to coenuro *Taenia serialis*. In the histological preparation it was observed: muscle tissue, connective tissue fibroblasts and an inflammatory surrounding area composed of eosinophils and lymphocytes which in turn limited the parasite scolices. This finding represents an important condition to evaluate the natural environment of wild animals in the area, due to the risk of dissemination and contamination of plants and animals of the area, even though, may not be of public health importance, unless meat of wild rabbits gets eaten.

Keywords: *Taenia serialis*; coenurosis; wild rabbit; emerging disease.

1. Introduction

Domestic and wild carnivores are important reservoirs of tapeworms that affect hunting animals and other wildlife animals, it is well recognized that directly or indirectly carnivores play an important role as ecological routes of transmission of tapeworms to humans and pets, therefore, tapeworms contained in carnivores are important not only for parasitologists but also for veterinarians, biologists and physicians.

Ecological biology, pathogenicity, prevention and other aspects of the tapeworm, is very dispersed, knowing more about its phylogenetic position, hosts classes and geographic distribution.

Tapeworms of carnivores require two or more different species of hosts to complete their life cycles. The coenurosis is caused by consumption of food contaminated by dogs' feces or other feces of hosts carriers of tapeworm. The rabbit's coenurosis is a metacestodosis localized in muscle and subcutaneous tissue, produced by *Coenurus serialis*, a small intestine parasite of dogs and other canids. It measures 20 to 72 cm long. The larval stage of the tapeworm serialis has a prepatent period of 7 to 14 days, which is acquired by eating raw viscera containing coenuros.

2. Materials and Methods

Case review.

According to the person submitting the sample of muscle tissue - hydatid cyst to study; this sample was obtained from a wild rabbit near the ecological park area: Nevado de Toluca, which at that time was trapped and caught in a trap; apparently the animal did not show any clinical signs, and was sacrificed in order to take advantage of his flesh for feeding the family, however, at the time of evisceration no alteration

The aim of this study is to provide a current reference about the pathology of coenurosis in hares (wild rabbit), and determinants of its presentation on animal health, which can be of risk to human health, as well.

was seen, except an alteration located on the right thigh level of the animal, which measured 3 x 6 cm long, surrounded by soft connective and muscular tissue (Figures 1 and 2). The sample preparation, was done with 10% buffered formalin, for further histopathology, clear liquid was obtained containing soft mass and lots of scolices, the preparation ended with hematoxylin and eosin staining.

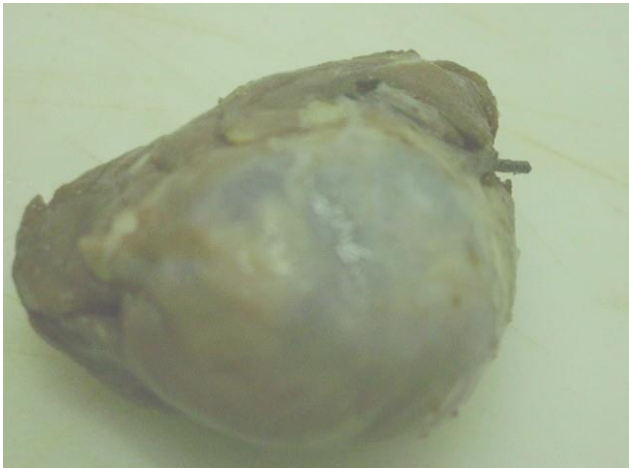

Figure 1. Hydatid cyst surrounded by muscle tissue of soft consistency

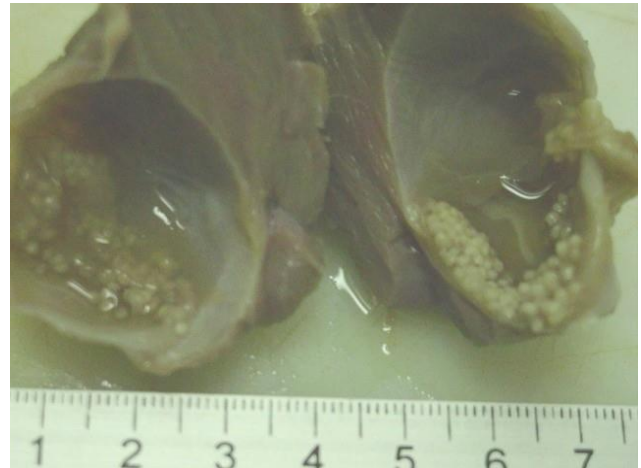


Figure 2. Sagittal section of hydatid cyst containing scolex of Taenia

Histopathology

In the prepared tissue, it was observed: muscle tissue, connective tissue and fibroblasts surrounding an inflammatory area composed of eosinophils and lymphocytes limiting to scolices of the *Tapeworm serialis* parasite (Figures 3 and 4).

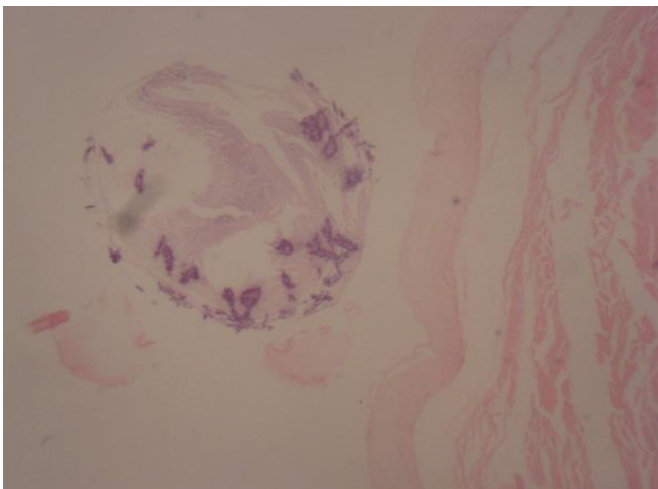


Figure 3. Histological section of muscle mass - cyst. Presence of capsule: fibroblasts and connective tissue surrounding scolex. H & E. 10X.

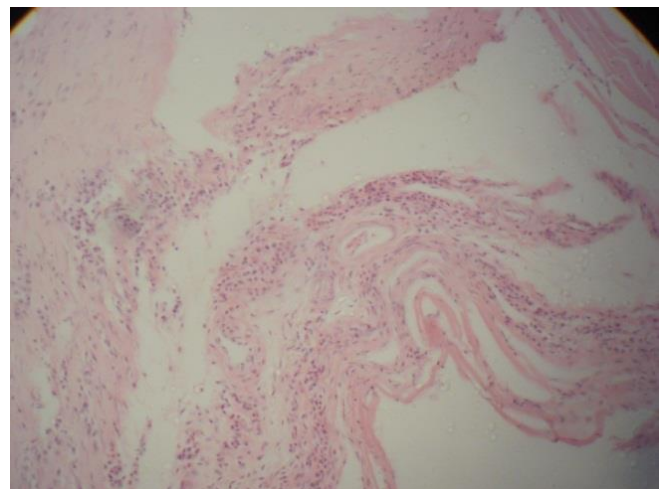


Figure 4. Histological section muscle mass - cyst. Inflammatory reaction (eosinophils - lymphocytes). H & E. 10X.

3. Discussion and Conclusion

A case of a rounded sample of muscular tissue, with an increased volume of 10 cm diameter was localized in the right thigh area of a wild rabbit, a soft mass was felt with complete delimitation of all edges.

For the diagnosis, it is usually examined the content of the nodules, once the diagnosis is confirmed coenuros can be removed surgically. At the beginig of diagnostic, a puncture was performed on the tissue, extracting transparent aqueous liquid, discarding an abscess or hematoma. Content analysis was observed and revealed the presence of many scolices, corresponding to coenuro *Tenia serialis*.

Coenurosis in connective tissue of leparopidae is caused by the larval stage of *Taenia serialis*. *C serialis* is similar to *C. multiceps*, but can be distinguished by the arrangement of the cephalic invaginations in linear position. The scolex measures from 900 microns to 1.3 mm, tends to form daughter internal and external vesicles. This cestodosis has a cosmopolitan distribution, lagomorphs are used as intermediate hosts, as well as certain rodents and weasels, as well as goats and rarely man, where coenuro develops. It has also been described in cats as an accidental host.

Coenurosis is caused by the consumption of food (fodder), proceeding from meadow contaminated by proglotides of dogs or other hosts of tapeworm carriers of *Taenia serialis*. The transmission is similar to that of cysticercosis, however the endogenous pathway migration does not occur by the hepatic parenchyma, so oncosphere spread through the liver by the

general circulation linfohemática for distribution throughout the body. Coenuros tissue as the transparent vesicles very variable dimensions from 2 to 15 cm in diameter develop, according to their location and numerous scolex inside. They reach their infective capacity within 2 to 3 months post ingestion and their longevity is at least two years. Cysts develop in the connective tissue and muscle fascias of hares and rabbits, especially in the neck, back, chest, as well as in kidneys, peritoneum and occasionally in spinal cord and brain.

Clinical signs are due to comprehensive action of coenuros and vary according to their location. Coenuros located in muscle can be compressed and elongated, while subcutaneous can reach large dimensions and could be clinically diagnosed by palpation, where they can be appreciated as cold and easily movable nodules.

This tapeworm infection takes place when the eggs of *Taenia serialis* contained in the small intestine of dogs are ingested, the cenuro reaches its development in three months, the dogs are infected by eating infected rabbits with *C. serialis*. Clinically coenurosis of subcutaneous connective tissue manifests with a soft, cold, painless, mobile rounded swelling, reaching different areas of the body such as chest wall, back, thighs and head. When it occurs in the head region, causes mandibular deviation, other cenuros are transformed into abscesses causing hot and painful injurier when rubbed; when they appear in the eyes clinically ophthalmia occurs. There may also be paresis or paraplegia when infestations occur in subarachnoid, causing spinal cord compression. When the parasite is presented in subpleural tissue, there are respiratory problems such as shortness of breath.

The general health is unaffected except in heavy infestations.

The parasitic infection due to *Coenurus serialis* in subcutaneous tissue of rabbits and hares, clinically presents subcutaneous swelling with the size of a lemon. At the necropsy vesicles are in various locations, wrapped in a membrane perivascular by host reaction. Sometimes there are lesion tissue necrosis due to the action of the vesicular fluid which diffuses and has cytotoxic action are observed.

O'Reilly *et al.* (2002) reported a case of ocular location which originated exophthalmia from the right eye in a rabbit; literature report cases by these authors and this case are limited, therefore, such diseases should be considered a risk factor not only for animal health but also to humans.

Usually, the diagnosis is made at necropsy by observing and identifying characteristic vesicles. Specific treatment is not known; praziquantel could have an effect, it could be useful for preventing this pathology to avoid green fodder contaminated with feces of dogs, or throw dead rabbits outdoors.

Because there is no pharmacological treatment for coenurosis it is important to take preventive measures in dogs, avoid feeding raw viscera containing cysts, as well as periodic and timely treatment against taenia. In domestic animals and in free-living (wildlife), there is a risk of contamination of various diseases. Parasitic

diseases originate in animals as long as the parasite is maintained in any of the natural hosts, either intermediate or final hosts, which should be a precedent for the attention and care of wildlife specialists.

This present finding detected in hares, is an important condition to evaluate the natural environment of animals in the area, it represents an important case study because of the risk it represents for the animals of that area, contagion and contamination of the vegetables consumed by animals that coexist in it, until now considered as not of public health importance.

References

1. Bowman, D.D.; Lynn, R.C.; Eberhard, M.L. Parasitología para veterinarios. 8ª ed. Elsevier, España, S.A. 2004.
2. Cabello, C. Consideraciones sobre la importancia de las enfermedades de los animales silvestres. Rev. Soc. Med. Vet. Chile, 1994. 24: 24-28.

3. Carl, L.R.; Eberhard, M.L. Parasitología para Veterinarios. 8ª ed. Elsevier, Saunders. Madrid, España. 1987.
4. Cordero del Campillo, M.F.A.; Rojo, A.; Martínez, C.; Sánchez, S.; Hernández, I.; Navarrete, P.; Diez, H.; Quiroz, M.; Carvalho, R. Parasitología Veterinaria. Mc Graw - Hill. Interamericana. Madrid, España. 2001.
5. Courtin, S.; Alcaino, H.; Plaza, J.; Ferreire, G. Platelminfos del conejo silvestre (*Oryctolagus cuniculus*) en la cordillera de Nahuelbuta. Chile. Arch Med Vet., 1989; 11 23-26.
6. Davis, J.W.; Anderson, R.C. Enfermedades parasitarias de los mamíferos salvajes. Acribia. Zaragoza, España. 1983.
7. González-Herrera, L.E.; Valladares-Carranza, B.; Ortega-Santana, C.; Zamora-Espinosa, J.L.; Castro-Maruri, J.; Velázquez-Ordóñez, V.; Peña-Betancourt, S.D. Cenurosis subcutánea en una liebre (*Lepus spp*), de la reserva ecológica “Nevado de Toluca”, México. REDVET. 2011; 12(11) <http://www.veterinaria.org/revistas/redvet/n111111.html> (Diciembre 2016).
8. Hendrix, M.C. Diagnostic Veterinary Parasitology. 2ª ed. Mosby, Inc. U.S.A. 1998.
9. Huss, B.T.; Miller, M.A.; Corwin, R.M.; Hoberg, E.P.; O'brien, D.P. Fatal cerebral coenurosis in a cat. Am. Vet. Med. Assoc., 1994; 205: 69-71.
10. O'Reilly, A.; Mccowan, C.; Hardman, C.; Stanley, R. Taenia serialis causing exophthalmos in a pet rabbit. Ophthalmol., 2002; 5, 227-230.
11. Quiroz, R.H. Parasitología y Enfermedades Parasitarias de los Animales Domésticos. Noriega. México, D.F. 1999.
12. Urquhart, G.M.; Armour, J.; Duncan, J.L.; Dunn, A.M.; Jennings, F.W. Parasitología Veterinaria. Acribia. Zaragoza, España. 2001.
13. Valladares, C.B.; Zamora, E.J.L.; Castro, M.J.; Gutiérrez, C.A.; Velázquez, O.V.; Ortega, S.C.; Alonso, F.U. Clinicopathologic study of *Bordetella bronchiseptica* in rabbits submitted for diagnosis at CIESA-UAEMEX. World Rabbit Sci., 2015; 23 (1): 75. <http://dx.doi.org/10.4995/wrs.2015.3531>
14. Valladares-Carranza, B.; Ortega-Santana, C.; Velázquez-Ordóñez, V.; Zamora-Espinosa, J.L.; Peñuelas-Rivas, C.G.; Castro-Maruri, J.; Talavera-Rojas, M.; Alonso-Fresan, M.U.; Zaragoza-Bastida, A. *Bordetella bronchiseptica* como un riesgo importante de salud pública. Estudio clínico patológico en conejos. REDVET. 2011; 12 (10) <http://www.veterinaria.org/revistas/redvet/n101011.html> (Diciembre 2016).
15. Zamora, E.J.L.; Valladares, C.B.; Fajardo, M.R.C. Diseases diagnosed in rabbits sent to CIESA from the valley of Toluca during 2004 to 2013. World Rabbit Sci., 2015; 23 (1): 77. <http://dx.doi.org/10.4995/wrs.2015.3531>